


ORIGINAL RESEARCH

Open Access



Laparoscopic donor nephrectomy: technique and outcome, a single-center experience

Osama Zaytoun^{1*} , Moustafa Elsayy¹, Kareem Ateba², Ayman Khalifa², Ahmed Hamdy¹ and Ahmed Mostafa¹

Abstract

Background: Laparoscopic donor nephrectomy (LDN) has been established as a surgical standard for living kidney donation. The aim of this work is to report our own experience with LDN regarding outcome and technique.

Methods: We prospectively identified 110 LDN cases between May 2017 and April 2020. Donor case files and operative notes were analyzed for age, sex, laterality, body mass index, warm ischemia time (WIT), intraoperative and postoperative complications, operative time, and length of hospital stay (LOS). Data were analyzed using SPSS version 10 (SPSS: An IBM Company, IBM Corporation, Armonk, NY, the USA).

Results: The mean age was 38 years, and 77% were males. Three cases (2.72%) required conversion to conventional open donor nephrectomy (ODN). Nevertheless, none of cases required intraoperative blood transfusion. The mean WIT was 2.6 min. Two cases (1.8%) developed major vascular injury (Clavien grade IIIb) and required conversion to ODN. Postoperatively, one patient (0.9%) needed transfusion of one unit of packed RBCs (Clavien grade II). The mean LOS was 2 days. Most common early postoperative complication was ileus (Clavien grade II) that developed in 4 (3.6%) cases. Incisional hernia (Clavien grade IIIb) was encountered in two (1.8%) cases. Two (1.8%) cases developed wound infection at the incision site and treated conservatively (Clavien grade I).

Conclusions: LDN is a safe technique with accepted intraoperative and postoperative morbidity. It offers short hospital stay, better cosmesis and early convalescence. In experienced hands, it can effectively deal with various vascular and ureteral anomalies without compromising early graft function.

Keywords: Kidney transplantation, Laparoscopy, Donor nephrectomy

1 Background

Compared to dialysis, kidney transplantation is the best treatment option for patients with end-stage renal disease (ESRD), with significantly better survival rates [1]. Advancement in surgical techniques, improvements in postoperative care, specialized immunosuppressive treatment protocols, and increased rate of live kidney donations have certainly improved kidney transplant outcomes [2]. Additionally, live kidney donation offers

numerous significant advantages, including shorter waiting time for transplantation, higher quality renal grafts, elective surgical setting, and an opportunity for a preemptive transplant [3, 4].

In 1995, Ratner performed the first laparoscopic donor nephrectomy (LDN), which later became the most accepted standard surgical technique for donor surgery in renal transplantation [5]. Since it was first applied and till now, LDN has continuously evolved with various modifications and approaches and has become the gold standard. Moreover, multiple studies demonstrated short- and long-term results which are comparable to open donor nephrectomy [6–8].

*Correspondence: ozaytoun@gmail.com

¹ Department of Urology, Faculty of Medicine, University of Alexandria, Alexandria, Egypt

Full list of author information is available at the end of the article

A low rate of complications for the donors and adequate graft function should always be the critical targets for any transplantation team. Application of minimally invasive technique for kidney donations obtains a great advantage in terms of increased compliance with donation when the laparoscopic technique is accessible [8–13]. Worldwide, the living kidney donation rate increased significantly after the implementation of minimal invasive donor nephrectomy techniques [3, 13].

LDN has reported acceptable donor morbidity and mortality while achieving favorable graft outcomes. LDN decreases the incidence of adverse outcomes of open living-donor nephrectomy and improves the prospects of LDN, thus making it more appealing to prospective donors. LDN decreases postoperative pain, shortens convalescence, and improves cosmetic outcomes [13–16].

We started our first LDN in our center (Almowasah Alexandria University Hospital) in May 2017. The aim of this work is to report our own experience with LDN in terms of outcome as well as our technique.

2 Methods

We identified 110 LDN cases that were performed between May 2017 and April 2020 in Almowasah Alexandria University hospital to be included in the study. Each donor has been assessed preoperatively to exclude any medical and surgical conditions that could be a contraindication for renal donation. This assessment encompassed detailed medical, surgical, and drug history. Complete clinical examination was performed. Laboratory and radiological investigations were reviewed. Each donor was subjected to a regular follow-up period up to 3 months after surgery. All complications were graded according to Clavien–Dindo [17]. Data were analyzed using SPSS version 10 (SPSS: An IBM Company, IBM Corporation, Armonk, NY, the USA).

The following data were collected for each donor.

2.1 Preoperative

- Demographics (Age, Gender)
- Body mass index (BMI)
- Living related or Living unrelated
- Laboratory
 - Complete blood count.
 - Coagulation profile
 - Electrolytes
 - Renal function tests
 - Liver function test
 - Viral markers
 - Urine tests and analysis
 - Parathormone level

- Blood grouping
- Human leukocyte antigen (HLA) typing
- Flow cytometric cross-matching with the recipient.

– Radiological

- Chest X-ray.
- Echocardiogram
- Ultrasound abdomen & pelvis.
- Renal isotope scanning.
- Renal computerized tomography (CT) angiography: Radiological variations related to renal vasculature or the ureter.

2.2 Operative

- Side (right or left)
- Operative time
- Warm ischemia time (WIT): defined by the time lapse between application of the first Hem-o-lock to the renal artery (the second renal artery in cases of double arteries) and delivering the kidney in to the bedside ice basin on the back table
- Estimated blood loss (EBL)
- Need for blood transfusion
- Intraoperative complications
- Need to conversion to open
- Incision length

2.3 Postoperative

- Length of hospital stay (LOS).
- Need for blood transfusion.
- Postoperative complications.

2.4 Anesthetic consideration for LDN

Under routine general anesthesia, two wide bore cannulae were inserted. Diuresis is induced by mannitol 20% (1 g/kg IV) or by using furosemide (0.5–1 mg/kg IV) in few cases. Pain control is done either by narcotics or paravertebral block. Urine output was maintained at a brisk rate using aggressive intravenous hydration, supplemented with diuretics, and 5000 U of unfractionated heparin (when there was no contraindication) was given just prior to the renal artery occlusion.

2.5 Surgical technique

The technique was transperitoneal laparoscopic procedure, given the increased security that it provides to the

surgeon. Patients were in a flexed, lateral decubitus position, we use closed entry technique in all cases. Pneumoperitoneum is initiated by Veress needle at Palmer's point with initial pressure adjusted at 10–12 mmHg. Then, 1.5 cm incision at or above umbilicus for visual trocar 10 mm trocar then another 2 trocars inserted under vision 10 mm trocar below costal margin and 4 finger away from visual trocar and 5 mm trocar at the Mcburney point for right LDN and reverse in left donor nephrectomy (Fig. 1).

The procedure commences by reflecting the colon at white line till we reach ureter or gonadal vein as landmark then completely dissecting cephalic along the ureter till we reach the pedicle, we use harmonic scalpel in all cases for dissection (Fig. 2).

Then, we completely dissect and skeletonize the artery and the vein using harmonic scalpel and laparoscopic Maryland grasper. Gonadal and lumbar veins were controlled. Then, we completely free the upper pole and lateral border of the kidney (Fig. 3).

When we are ready, small incision is done at the site of the lower trocar about 3–8 cm we cut till superficial muscle layer. The innermost muscle layer is left intact at this point to keep the pneumoperitoneum till hilar control and specimen extraction. We use Hem-o-lock Polymer Ligating Clips Medium sized for controlling artery, vein and ureter.

We start first by controlling the ureter at the level of pelvic brim by application of one clip without cutting the ureter. Afterward, renal artery is controlled by application of two clips; then, renal vein is controlled by another two clips. We then proceed with cutting the artery, vein and lastly ureter just proximal to the previously applied clips using laparoscopic scissors. At this point, the kidney becomes completely free of any attachment. A laparoscopic grasper is introduced through the trocar at the extraction site to grasp the kidney by its perinephric fat.

Pneumoperitoneum is discontinued at this point. Incision at the extraction site is completed by incision

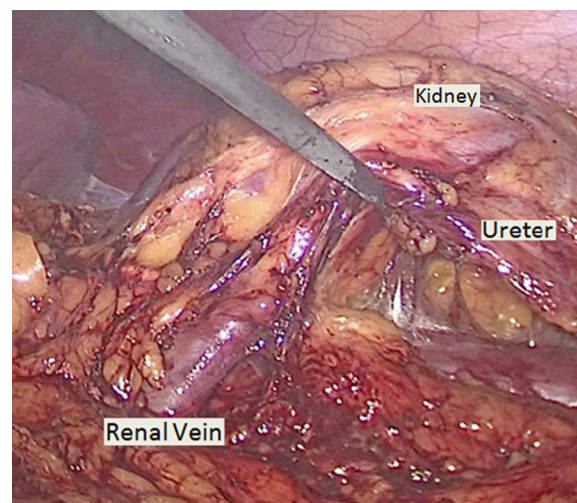


Fig. 2 After reflecting the colon, the ureter is being followed till the pedicle in Lt LDN

of inner muscle layers and peritoneum using electrocautery. The kidney is dragged by pulling the grasper out of the incision, and the kidney is gently delivered into kidney basin with ice for perfusion.

The inner muscle layer of the incision is closed. Then, we re-establish pneumoperitoneum again to check hemostasis. If further clip is required for hemostasis, we re-insert the 10-mm trocar again through the incision under vision. 18 Fr nylon catheter drain is placed under vision usually from visual trocar. Incision is closed in layers.

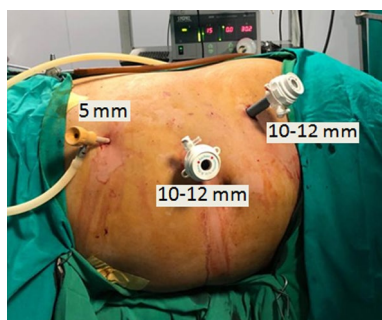


Fig. 1 Trocar position for Lt LDN

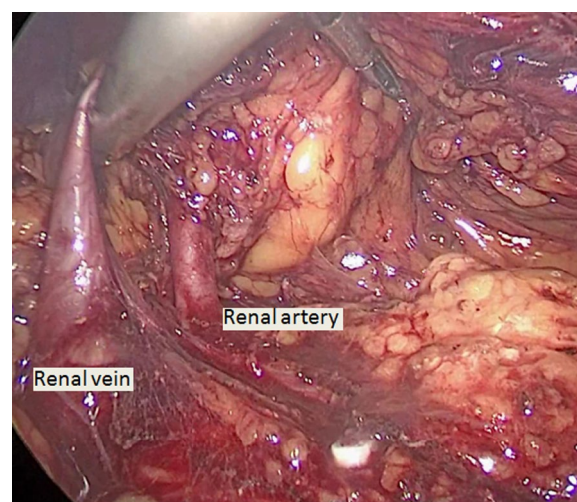


Fig. 3 Completely dissecting renal artery and vein (left LDN)

The postoperative protocol included analgesia with intravenous ketorolac on-demand (limited number of doses for only one day), removal of the Foley catheter on postoperative day 1 and advancing to a regular diet on day 2.

3 Results

The mean age for the studied donors was 38 years, and 77% were males. Regarding the relation with the recipient, 80% of donors were not related. 19 (17%) cases possessed more than one renal artery (accessory or double renal artery). One case had a double ureter down to the bladder (Table 1).

Table 2 shows operative parameters for the study group. Left kidney was retrieved in most of cases (75.4%). Three cases (2.72%) required conversion to conventional open donor nephrectomy (ODN). Nevertheless, none of cases required intraoperative blood transfusion. The mean WIT was 2.6 min. Two cases (1.8%) developed major vascular injury (Clavien grade IIIb), and this necessitated conversion to ODN.

Postoperatively, one patient (0.9%) needed transfusion of one unit of packed RBCs (Clavien grade II). The mean LOS was 2 days. Most common early postoperative complication was ileus (Clavien grade II) that developed in 4 (3.6%) cases. Incisional hernia (Clavien grade IIIb) was encountered in two (1.8%) cases. Two (1.8%) cases developed wound infection at the incision site and treated conservatively (Clavien grade I) (Table 3).

4 Discussion

Donor nephrectomy has always been considered a unique major procedure because the operation involves an otherwise healthy individual subjected to the hazards of a major operation entirely for altruistic purposes [18, 19]. Additionally, the ultimate graft function can be

Table 2 Intraoperative data for the study population

Kidney side, No (%)	
Left	83 (75.4%)
Right	27 (24.6%)
EBL, ml (range) mean \pm SD	(60–500) 100 \pm 40
Operative time, min (range) mean \pm SD	(52–170) 72.8 \pm 16.2
WIT, min (range) mean \pm SD	(1.5–5) 2.6 \pm 1.1
Conversion to open, no (%) / Clavien Grade	3 (2.72%) / IIIb
Need for blood transfusion, no (%)	0 (0%)
Length of incision, cm (range) mean \pm SD	(7–12) 9 \pm 1.2
Intraoperative complications, no (%) / Clavien grade	
Major vascular injury	2 (1.8%) / IIIb

hazardously affected by complications that may happen during donor surgery [20].

LDN has revolutionized the living kidney transplantation and has made donation more appealing. With comparable functional outcomes, LDN offers shorter LOS, less postoperative pain, a faster return to normal activity and improved cosmesis. Demonstrating safety and faster recovery has resulted in increase in the number of living donation since its adoption as a gold standard technique in the last decades [13–16].

After a long experience in ODN, we started to apply transperitoneal LDN to keep pace with development in the donor techniques in our center. During this period, we collected data of 110 LDN to share our technique and outcomes in 3-year experience. While the literature is replete with LDN series that encompass even much more number of cases [16], we still believe that our data worth publishing and that our experience to be shared. First, we are unaware of any previous study from Egypt that discusses LDN or including this number of cases. Second, LDN is still considered a novel technique to be adopted with this rate of cases in our country and our center possesses the highest LDN volume during the last few years. Third, while the financial aspects held against the use of modern and relatively expensive laparoscopic tools like vascular staplers for hilar control and disposable bags for specimen extraction. Alternatively, we used traditional relatively non-expensive tools that fit our economics and still showed high reliability and safety. This makes LDN

Table 1 Demographics and preoperative data

Age, ys (range) mean \pm SD	(22–50) 38 \pm 12
Sex, no (%)	
Male	85 (77%)
Female	25 (23%)
BMI, kg/m ² (range) mean \pm SD	(23–32) 28.7 \pm 2
Relationship, no (%)	
Living related	22 (20%)
Non-related	88 (80%)
Vascular and ureteral variations on preoperative CT, no (%)	
Non-single renal artery	19 (17%)
Non-single renal vein	5 (4.5%)
Ureteral duplication	1 (0.9%)

Table 3 Postoperative findings for the study population

LOS, days (range) mean \pm SD	(1–6) 2.0 \pm 1.0
Need for blood transfusion, no (%) / Clavien grade	1 (0.9%) / II
Postoperative complications, no (%) / Clavien Grade	
Wound infection	2 (1.8%) / I
Ileus	4 (3.6%) / II
Incisional hernia	2 (1.8%) / IIIb

still applicable in other centers with similar financial circumstances.

We opted in this study to focus on LDN regarding technique and outcomes. Worth to mention that we did not encounter any graft insults during recipient surgery. Recipient surgeons were satisfied with the resultant vascular and ureteral anatomy that allowed easy anastomosis. However, this was not mentioned in our results as it is beyond the scope of this study. Additionally, we did not compare LDN to our previous and concurrent ODN cases as we chose only to focus on LDN performance in this work.

Some studies have questioned the safety of Hem-o-lock clips in sealing renal artery and vein [21, 22]. We confirmed their safety in our series as we did not get any complications regarding this issue. Left side was the most commonly retrieved side which is mindfully attributed to more favorable anatomy. A shorter right renal vein was managed by upwards traction of the freely mobilized kidney during Hem-o-lock application and placing the distal Hem-o-lock in flush with inferior vena cava. Additionally, LDN showed a great success in dealing with different vascular and ureteral variations without compromising graft function.

The overall outcome was in concordance with the LDN literature [13–16]. Despite the steep learning curve, our mean operative time was 72.8 min. It should be stated that LDN was performed by surgeons with excellent laparoscopic skills for other kidney procedures but not LDN. Moreover, they possess frequent exposure to ODN. These combinations of skills may have had impact on mastering this newly adopted technique in a relatively short period.

This study may be regarded as a smooth transition from the ODN to the LDN. This transition is exhibited by a low conversion rate to ODN. Three cases were converted to ODN, first two cases represented our initial experience and were due to bleeding and these two patients did not require blood transfusion or surgical re-exploration. The third case was converted because of complex anatomy and hence failure to progress. We do not have any experience in hand-assisted laparoscopic nephrectomy or any available equipment for this approach, and thus, the conversion was directly to ODN.

Additionally, our LDN complication rate was also comparable with the rates reported in this literature [13–16, 23, 24]. We encountered a total of 9/110 (8.1%) postoperative complications and most of them were managed conservatively. Two cases developed postoperative incisional hernia. These two patients were specifically of high BMI, and surgical closure of extraction site was demanding. They sought surgical correction beyond the designed 3-month follow-up period with mesh repair. The mean LOS was 2 days. Few patients required longer stay which

was directly related to operative and postoperative complications, especially postoperative ileus. On patient received one unit of packed RBCs due to low postoperative hemoglobin level owing to previously mentioned intraoperative incidence of bleeding.

WIT was comparable with the literature [13–16]. We followed three technical tips in a trial to minimize the WIT to lowest possible level even if theoretically. First, confirming that the kidney is completely mobilized without any peripheral attachments prior to pedicle control. Second, we start with application of first Hem-o-lock to the ureter before arterial clipping. Lastly, incision of skin, subcutaneous fat and outer muscle layer shortens the period of specimen extraction while still keeping effective pneumoperitoneum.

Despite being beyond the aim of this study, our grafts survival rates were comparable to those reported in recent studies [16, 25]. However, another study with a longer period of follow-up is essential to better elucidate this conclusion.

Some limitations do exist for the current study. First, it did not include a comparison with ODN arm that will certainly better show the impact of LDN on donor morbidity, postoperative pain, hospital stay. Second, we did not include a cost analysis that may play a vital role in the applicability of such procedure in developing countries. Third, a longer follow-up period may be required to better assess graft function as well as renal function changes in donors.

5 Conclusion

LDN is a safe technique with accepted intraoperative and postoperative morbidity. It offers short hospital stay, better cosmesis and early convalescence. In experienced hands, it can effectively deal with various vascular and ureteral anomalies without compromising early graft function.

Abbreviations

ESRD: End-stage renal disease; LDN: Laparoscopic donor nephrectomy; BMI: Body mass index; CT: Computerized tomography; WIT: Warm ischemia time; EBL: Estimated blood loss; LOS: Length of hospital stay; ODN: Open donor nephrectomy.

Acknowledgements

Not applicable

Authors' contributions

OZ was involved in design of the work, data acquisition. ME contributed to data acquisition. KA was involved in data analysis. AK and AM contributed to drafting the work and revision of the Draft. AH was involved in data Interpretation and drafting the work. All authors have approved the submitted version (and any substantially modified version that involves the author's contribution to the study); all authors have agreed both to be personally accountable for the author's own contributions and to ensure that questions related to the accuracy or integrity of any part of the work, even ones in which the author was not personally involved, are appropriately investigated, resolved, and the

resolution documented in the literature. All authors have read and approved the manuscript.

Funding

None.

Availability of data and material

Not Applicable.

Declarations

Ethics approval and consent to participate

The ethics committee of the Faculty of Medicine, University of Alexandria has approved this prospective study. Reference number: 0305178. Informed consent has been taken from patients or the patients guardians.

Competing interests

The authors declare that they have no competing interests.

Consent for publication

Not Applicable.

Author details

¹Department of Urology, Faculty of Medicine, University of Alexandria, Alexandria, Egypt. ²Department of Anaesthesiology, Faculty of Medicine, University of Alexandria, Alexandria, Egypt.

Received: 16 June 2021 Accepted: 28 August 2021

Published online: 17 November 2021

References

- Guler S, Cimen S, Hurton S, Molinari M (2015) Risks and benefits of early catheter removal after renal transplantation. *Transplant Proc* 47:2855–2859
- Cimen S, Guler S, Alwayn I, Lawen J, Kiberd B (2013) Correlation of surgical times with laparoscopic live donor kidney transplant outcomes. *Open J Organ Transpl Surg* 3:68–72
- Kok NF, Weimar W, Alwayn IP, Ijzermans JN (2006) The current practice of live donor nephrectomy in Europe. *Transplantation* 82:892–897
- Dols LF, Kok NF, Terkivatan T, Tran TC, d'Ancona FC, Langenhuijsen JF, zur Borg IR, Alwayn IP, Hendriks MP, Weimar IM, Ijzermans JN (2010) Hand-assisted retroperitoneoscopic versus standard laparoscopic donor nephrectomy: HARP-trial. *BMC Surg* 10:11
- Ratner LE, Ciseck LJ, Moore RG, Cigarroa FG, Kaufman HS, Kavoussi LR (1995) Laparoscopic live donor nephrectomy. *Transplantation* 60:1047–1049
- Simforoosh N, Bassiri A, Siaee SA et al (2003) Laparoscopic versus open live donor nephrectomy: the first randomized clinical trial. *Transplant Proc* 35:2553–2554
- Al-Oraifi I, Tawfeeq M, Al-Hellow H et al (2017) Laparoscopic donor nephrectomy of dual renal artery kidneys: single center experience. *Chirurgia (Bucur)* 112:124–129
- Cadeddu JA, Ratner L, Kavoussi LR (2000) Laparoscopic donor nephrectomy. *Semin Laparosc Surg* 7:195–199
- Finelli FC, Góngora E, Sasaki TM, Light JA (2001) A survey: the prevalence of laparoscopic donor nephrectomy at large US transplant centers. *Transplantation* 71:1862–1864
- Schweitzer EJ, Wilson J, Jacobs S et al (2000) Increased rates of donation with laparoscopic donor nephrectomy. *Ann Surg* 232:392–400
- Lind MY, Hazebroek EJ, Kirkels WJ et al (2004) Laparoscopic versus open donor nephrectomy: ureteral complications in recipients. *Urology* 63:66–68
- Chung E, Grant AB, Hibberd AD, Spratt P (2007) Why potential live renal donors prefer laparoscopic nephrectomy: a survey of live donor attitudes. *BJU Int* 100:1344–1346
- Sozener U (2021) Laparoscopic live donor nephrectomy: single-center experience of 200 consecutive cases. *J Laparoendosc Adv Surg Tech A* 31(6):627–631
- Branco AW, BrancoFilho AJ, Kondo W et al (2005) Hand-assisted right laparoscopic live donor nephrectomy. *Int Braz J Urol* 31:421–429
- Su LM, Ratner LE, Montgomery RA et al (2004) Laparoscopic live donor nephrectomy: trends in donor and recipient morbidity following 381 consecutive cases. *Ann Surg* 240:358–363
- Cho SJ, Moon HW, Kang SM, Choi SW, Kim KS, ChoiYS HSH, Ha US, Lee JY, Kim SW, Kim JC, Cho HJ (2020) Evolution of laparoscopic donor nephrectomy techniques and outcomes: a single-center experience with more than 1000 cases. *Ann Transplant* 25:e918189
- Clavien PA, Barkun J, de Oliveira ML, Vauthey JN, Dindo D, Schulick RD et al (2009) The Clavien-Dindo classification of surgical complications five year experience. *Ann Surg* 250(2):187–196
- Kute VB, Vanikar AV, Shah PR, Gumber MR, Patel HV, Modi PR, Rizvi SJ, Shah VR, Modi MP, Kanodia KV, Trivedi HL (2014) Outcome of live and deceased donor renaltransplantation in patients aged 55 years: a single-centerexperience. *Indian J Nephrol* 24:9–14
- Matas AJ, Payne WD, Sutherland DE, Humar A, Gruessner RW, Kandaswamy R, Dunn DL, Gillingham KJ, Najarian JS (2001) 2500 living donor kidney transplants: a single-centerexperience. *Ann Surg* 234:149–164
- Tsoufias G, Agorastou P, Ko DS, Hertl M, Elias N, Cosimi AB, Kawai T (2017) Laparoscopic open donor nephrectomy: lessons learnt from single academic center experience. *World J Nephrol* 6:45–52
- Ponsky L, Cherullo E, Moinezhadeh A et al (2008) The Hem-o-lok clip is safe for laparoscopic nephrectomy: a multi-institutional review. *Urology* 71(4):593–596
- Liu Y, Huang Z, Chen Y et al (2018) Staplers or clips?: A systematic review and meta-analysis of vessel controlling devices for renal pedicle ligation in laparoscopic live donor nephrectomy. *Medicine (Baltimore)* 97(45):e13116
- Mohsin R, Shehzad A, Bajracharya U et al (2018) Laparoscopic donor nephrectomy: early experience at a single center in Pakistan. *Exp Clin Transplant* 16(2):138–142
- Carrión DM, Gómez Rivas J, Aguilera Bazán A et al (2019) Laparoscopic donor nephrectomy versus open donor nephrectomy: outcomes from a single transplant center. *Arch Esp Urol* 72(5):508–514
- Wang L, Zhu L, Xie X et al (2020) Long-term outcomes of laparoscopic versus open donor nephrectomy for kidney transplantation: a meta-analysis. *Am J Transl Res* 12(10):5993–6002

Publisher's Note

Springer Nature remains neutral with regard to jurisdictional claims in published maps and institutional affiliations.