

ORIGINAL RESEARCH

Open Access



Outcomes of nephron sparing surgery and cortical sparing adrenalectomy in the management of Von Hippel–Lindau syndrome

Selvin Theodore Jayanth, Partho Mukherjee*, Arun Jacob Philip George, J. Chandrasingh, T. J. Nirmal, Rajiv Paul Mukha, Santosh Kumar and Antony Devasia

Abstract

Background: The management of Von Hippel–Lindau syndrome (VHLS) is multidisciplinary. The urologist is involved in treating the renal, epididymal tumors and often adrenal pheochromocytoma. Preservation of renal and adrenal function is a challenge. We present 17 cases of VHLS in a tertiary care center in South India.

Methods: A retrospective review of the patients who underwent surgical treatment under urology for VHLS from January 2009 to November 2018 was conducted. The demographic data, the spectrum of manifestation, treatment, change in glomerular filtration rate, adrenal insufficiency, and recurrence-free survival were analyzed.

Results: There were 17 patients diagnosed with VHLS. The median age of diagnosis was 39 years (range 23–41). The spectrum of clinical manifestation was: multifocal RCC (88%), pancreatic cysts/tumors (70%), cerebellar hemangioblastoma (59%), retinal angiomas (47%), epididymal cysts/tumors (47%), pheochromocytomas (41%), and spinal hemanangiomas (30%). There were seven patients with ten pheochromocytoma lesions. Three underwent cortical sparing and seven total adrenalectomies; 13 patients underwent nephron sparing surgery (NSS), of which seven patients had bilateral tumors. The median duration of follow-up was 6.5 years (range 2–12 years). Following NSS, seven patients had a local recurrence, and one developed pancreatic metastasis. Two patients (11%) were lost to follow-up. Renal function was preserved in all patients at the last follow-up, and there was no postoperative adrenal crisis or mortality.

Conclusion: Nephron sparing surgery and cortical sparing adrenalectomy are the treatment of choice for multifocal RCC and pheochromocytomas in patients with VHLS providing good oncological outcomes and preservation of renal and adrenal function.

Keywords: VHLS, Nephron sparing surgery, Cortical sparing adrenalectomy

1 Background

Von Hippel–Lindau syndrome (VHLS) is a rare genetic disorder with multisystem involvement due to the mutation in the VHL gene (tumor suppressor) on chromosome 3p25. Eugen Von Hippel described angiomas in the eye in 1904 [1], and Arvid Lindau described the angiomas

of the cerebellum and spine in 1927 [2]. Renal cell carcinoma is a common presenting feature in patients diagnosed with Von Hippel–Lindau syndrome, occurring in 45–50% of the cases, often bilateral [3]. Pheochromocytomas involving unilateral or bilateral adrenal glands occur in 10% of patients.

The urologist is involved in managing renal cell carcinoma, pheochromocytoma, epididymal cysts, and cystadenomas. The disease is often multiple and bilateral,

*Correspondence: parthonline1981@gmail.com
Department of Urology, CMC Hospital, Vellore, Tamil Nadu 632004, India

so organ preservation (nephron and adrenal sparing surgery) is paramount. There is a lack of data from India. We present a review of patients with VHLS, emphasizing achieving oncological clearance and preservation of renal and adrenal function.

2 Methods

The institutional ethics and research board approved this study (IRB Min. No. 13781 dated 27.01.2021.) Retrospective review of patients operated under urology for VHLS from the department's electronic database was done from January 2009 to November 2018. The follow-up was up to November 2020. The demographic data, the spectrum of manifestation, treatment, renal functional outcome, recurrence-free survival, adrenal function, and overall survival were analyzed.

2.1 Diagnosis and classification of VHLS

The following clinical criteria are used for the diagnosis of VHL disease [4]

1. Patients with a family history of developing hemangioblastoma in the central nervous system, retinal angioma, renal cell carcinoma, pheochromocytoma or pancreatic tumors or cysts, and epididymal cystadenoma.
2. Patients without a family history of VHL disease but who develop hemangioblastoma or retinal angioma in combination with other tumors, such as renal cell carcinoma, pheochromocytoma, pancreatic tumors or cysts, or epididymal cystadenoma.

VHL syndrome is divided into two types depending on the risk of development of pheochromocytoma. Type 1 is characterized by a high risk of renal cell carcinoma and a low risk of pheochromocytoma (less than 10%). In type 2, there is a 40–60% chance of developing pheochromocytoma. In Type 2a the incidence of clear cell renal cell carcinoma is rare, whereas, in type 2b, there is a high risk of both renal cell carcinoma and pheochromocytoma. Type 2c is characterized by an increased risk of pheochromocytoma [5].

2.2 Preoperative evaluation

Apart from a detailed personal and family history, all underwent a head-to-toe examination and blood pressure measurement. Renal function tests and urinary metanephrine levels were checked. A thorough evaluation of all the possible manifestations of VHLS was carried out. An MRI brain, contrast-enhanced computed tomogram (CECT) of the abdomen, retinal evaluation, and examination of the genitalia were performed in all patients. A scrotal ultrasound was performed if

indicated. Those recruited after the year 2012 underwent a VHL gene (3p25) mutational analysis by the medical genetic department of the institution. The family members of these patients were referred to the medical genetics department of the institution and underwent familial counseling and screening. If the patients were diagnosed with pheochromocytomas, it was managed on a priority basis. Adrenalectomy was combined with NSS on the same side if required. Bilateral adrenal tumors were operated on at the same time. Patients who required multiple operations (cerebellar tumor excision and retinal angioma photocoagulation) underwent the procedure with an interval of 3–6 months between them.

2.3 Nephron sparing surgery

All patients underwent open nephron sparing surgery (NSS). Some patients who required more than one NSS for complete oncological clearance (bilateral tumors) as a staged procedure were performed after six months of the first NSS. A ureteric catheter was placed in the pelvis at the discretion of the operating surgeon. The kidney was cooled after clamping the renal vessels by surface cooling with ice slush. The tumors were enucleated, preserving as much of normal parenchyma. Intrarenal tumors were identified using intraoperative ultrasound. Large cysts were de-roofed and cyst wall excised. The renal defect was closed with perinephric fat or surgical. Any breach in the pelvicalyceal system was repaired with 4–0 catgut or PDS (polydioxanone sodium). A perinephric drain was placed, which was removed after 2–3 days.

2.4 Adrenalectomy

Pheochromocytoma was diagnosed based on clinical presentation and radiological criteria [6] on contrast-enhanced CT scan and estimating serum/urinary metanephrine and normetanephrine levels. MIBG (meta-iodo-benzyl-guanidine) scan was done in all patients to identify functional adrenal tumors, paragangliomas, and presence of metastatic lesions. Patients undergoing adrenalectomy were preoperatively admitted and optimized by the endocrinologists. They were transferred to the urology department a day before the surgery. They were adequately alpha- and beta-blocked according to the Roizen criteria [7]. Preoperative salt loading and adequate perioperative hydration were ensured. Those requiring NSS along with pheochromocytoma underwent an open operation, while those with isolated pheochromocytoma on one side underwent laparoscopic adrenalectomy. When bilateral adrenal pheochromocytomas were operated on, cortical sparing adrenalectomy was carried out on one side. Postoperatively they were managed in the surgical intensive care

unit. The urinary metanephrines were repeated after two weeks of the operation.

2.5 Follow-up

The patients were followed up at 10–14 days postoperatively and at 6-monthly intervals for the first two years and yearly after that with renal function tests, ultrasound (USG), or CECT/MRI (magnetic resonance imaging) abdomen and pelvis. The patients who had undergone adrenalectomy urinary metanephrines were checked.

2.6 Statistical analysis

Data were entered using EPI DATA software. Screening for outliers and extreme values was carried out using a Box-Cox plot and histogram (for the shape of the distribution). Summary statistics were used for reporting demographic, clinical, and laboratory characteristics. The trend of mean GFR from preoperative, immediate postoperative, and at the median follow-up was analyzed. Kaplan–Meier was used in estimating the recurrence-free survival.

3 Results

A total of 17 patients were diagnosed with VHLS during the study period (June 2009 to November 2018). 70% were males. The median age at diagnosis was 39 years (range 23–45). Positive family history was found in 59% of patients. The most common presenting complaint was hematuria (41%).

The patient characteristics are enlisted in Table 1. Fifteen patients (88%) presented with RCC, and all of them were multifocal. Ten patients had cerebellar hemangioblastomas (59%), and epididymal tumors were seen in 8(47%) of patients. Seven patients had pheochromocytomas (41%), of which three were bilateral (refer to Table 2).

Mutations involving the VHL gene on chromosome 3p25 were positive in all of the seven patients that were tested.

3.1 Nephron Sparing surgery

Fifteen patients had RCC all of which were multifocal. Of these, eight patients had unilateral, and seven patients had bilateral RCC. Among the eight unilateral multifocal RCC, two patients underwent radical nephrectomy and six patients underwent NSS. Among the seven patients with bilateral multifocal RCC, three patients underwent radical nephrectomy on the one side and NSS on the other; the remaining four patients underwent NSS on both sides. Intraoperative ultrasound was a helpful adjunct, especially for endophytic and hilar lesions. All patients had a clear cell pathology. Margins were positive in one patient (7%).

Table 1 Patient characteristics

Demographic data (n = 17)	Number (%)
Median age in years (range)	39 (23–45)
Sex	
Male	12 (70)
Female	5 (30)
Positive family history	10 (59)
Presenting complaint	
Incidental	3 (17)
Hematuria	7 (41)
Abdominal pain	3 (17)
Headache/hypertension	4 (23)
Others	2 (11)
Type of VHL	
1	10 (58)
2b	5 (30)
2c	2 (12)
Multifocal RCC	15 (88)
Pancreatic lesions	12 (70)
Cerebellar hemangioblastoma	10 (59)
Epididymal cysts/tumors	8 (47)
Retinal angiomas	8 (47)
Pheochromocytoma	7 (41)
Bilateral	3
Unilateral	4
Spinal angioma	5 (30)

One patient with a multifocal tumor involving both upper and lower poles, endophytic, had postoperative bleeding and urinary leak on the 2nd postoperative day and required re-exploration with the evacuation of hematoma and DJ stenting. In the 2nd and 3rd patients, the tumors were 3 cm in size and located at the upper pole and hilum. Postoperatively they developed a urinary leak and underwent DJ stenting, following which they had an uneventful recovery. The fourth patient (multifocal upper and interpolar endophytic tumor, 2–4 cm in size) had a mild urinary leak with high drain output for three days which gradually resolved with conservative management (refer to Table 3 and Fig. 1a, b).

3.2 Adrenalectomy for patients with pheochromocytoma

Seven patients were diagnosed to have pheochromocytomas. MIBG was positive for functional adrenal tumors in 6(85%) of the patients. Three had bilateral tumors and underwent cortical sparing adrenalectomy on the one side and total adrenalectomy on the other. The remaining with unilateral lesions had total adrenalectomy (refer to Table 4 and Fig. 2). All patients had an uneventful postoperative course, and none developed an adrenal crisis. Hence, in patients with bilateral pheochromocytomas,

Table 2 Spectrum of manifestation of VHLS

Patient number	Cerebellar hemangioblastoma	Retinal angioma	Pancreatic cysts/tumor	Adrenal pheochromocytoma	Multifocal RCC	Spinal lesions	Epididymal cysts
1	+	+	-	+	-	-	-
2	-	-	+	+	+	+	+
3	-	-	+	+	+	-	+
4 and 5	+	+	+	-	+	-	-
6 and 7	+	-	-	-	+	-	-
8	-	+	+	-	+	-	-
9 and 10	+	+	+	+	+	+	+
11	-	-	-	-	+	-	-
12	-	-	+	-	+	-	+
13		+	+	-	+	-	+
14	+	-	+	+	+	+	+
15	-	+	-	+	-	-	-
16	-	-	+	-	+	-	-
17	+	-	+	-	+	+	+
Total	10	8	12	7	15	5	8

Table 3 Nephron sparing surgery

N = 13	Number (%)
Unilateral (n = 8)	
NSS	6 (75)
Bilateral (n = 7)	
NSS on one side	3 (43)
NSS on both sides	4 (57)
The median size of tumors in cm (range)	3 (2–7)
Clear cell RCC	15 (100)
Number of tumors removed per partial nephrectomy (number/range)	2 (1–5)
Number of cysts removed per partial nephrectomy	3 (0–> 7)
Margin positivity	1 (7)
Complications	
Bleeding (Clavien Dindo III b)	1 (7)
Urinary leak (Clavien Dindo III b)	4 (30)
Perioperative hemodialysis (Clavien Dindo IVa)	1 (7)

the adrenal function can be preserved by cortical sparing adrenalectomy.

3.3 Preservation of renal function in patients undergoing NSS

Though there was a transient fall in the GFR in the immediate postoperative period, all the patients reached the preoperative GFR at their last follow-up (range 2–12 years). One patient required three hemodialysis sessions in the postoperative period; however, none had a decline in GFR at a median follow-up. All patients who

were available at follow-up had a GFR > 60 ml/1.73m² (refer to Fig. 3).

3.4 Other procedures performed

NSS and adrenalectomy were performed concomitantly. Apart from these procedures, five patients underwent cerebellar tumor excision. Of these, two patients were admitted with cerebellar tumors by the neurosurgery department and underwent excision of the same and, on evaluation were found to have renal tumors and referred for NSS. The other patients with small asymptomatic cerebellar lesions were kept on observation. Following management of the renal, adrenal, and cerebellar lesions, two patients underwent LASER photocoagulation for retinal angiomas associated with visual impairment. One patient underwent a distal pancreatectomy and splenectomy with a left open partial nephrectomy for a pancreatic cystadenoma. The epididymal cysts and cystadenomas were kept under observation.

3.5 Follow-up

The median duration of follow-up was 6.5 years (range 2–12 years). Seven of the 13 patients (53%) who underwent NSS had a local recurrence. Three underwent a second NSS. (Two patients who had unilateral RCC and one patient who had bilateral RCC underwent 2 NSS on the same side.) One developed a metastatic lesion in the pancreas (confirmed by endoscopic USG-guided biopsy) and was given Pazopanib (refer to Fig. 4). Two patients who developed recurrence were advised second NSS (11%) and were lost to follow-up. One patient developed a recurrence of < 2 cm, enhancing lesion at the renal hilum,

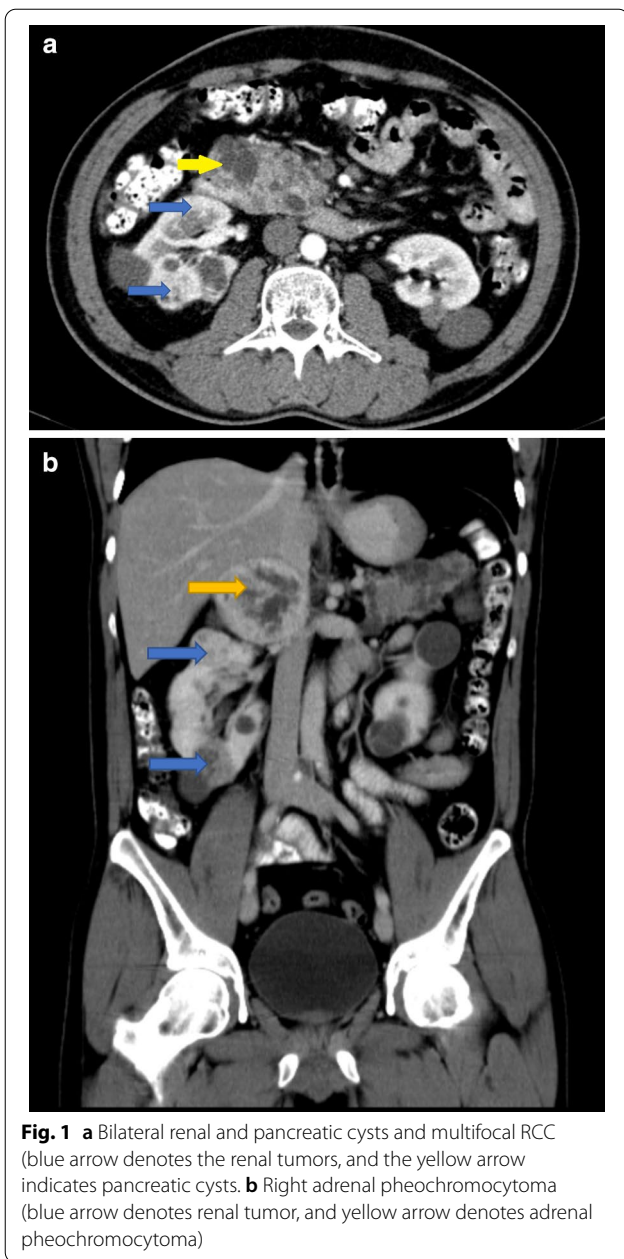


Fig. 1 **a** Bilateral renal and pancreatic cysts and multifocal RCC (blue arrow denotes the renal tumors, and the yellow arrow indicates pancreatic cysts). **b** Right adrenal pheochromocytoma (blue arrow denotes renal tumor, and yellow arrow denotes adrenal pheochromocytoma)

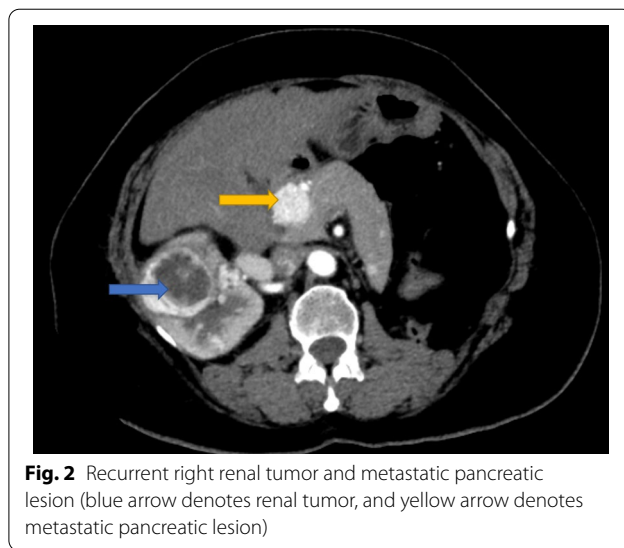


Fig. 2 Recurrent right renal tumor and metastatic pancreatic lesion (blue arrow denotes renal tumor, and yellow arrow denotes metastatic pancreatic lesion)

and was kept under observation in view of a solitary kidney status. The median recurrence-free survival was ten years (Range 2–12). There was no mortality.

4 Discussion

The management of VHL syndrome is multidisciplinary. The urologist’s challenge is to preserve renal and adrenal function in a multifocal, bilateral disease with a high propensity to recur [8]. The diagnosis is clinical and is aided by genetic analysis (3p25 germ-line mutation).

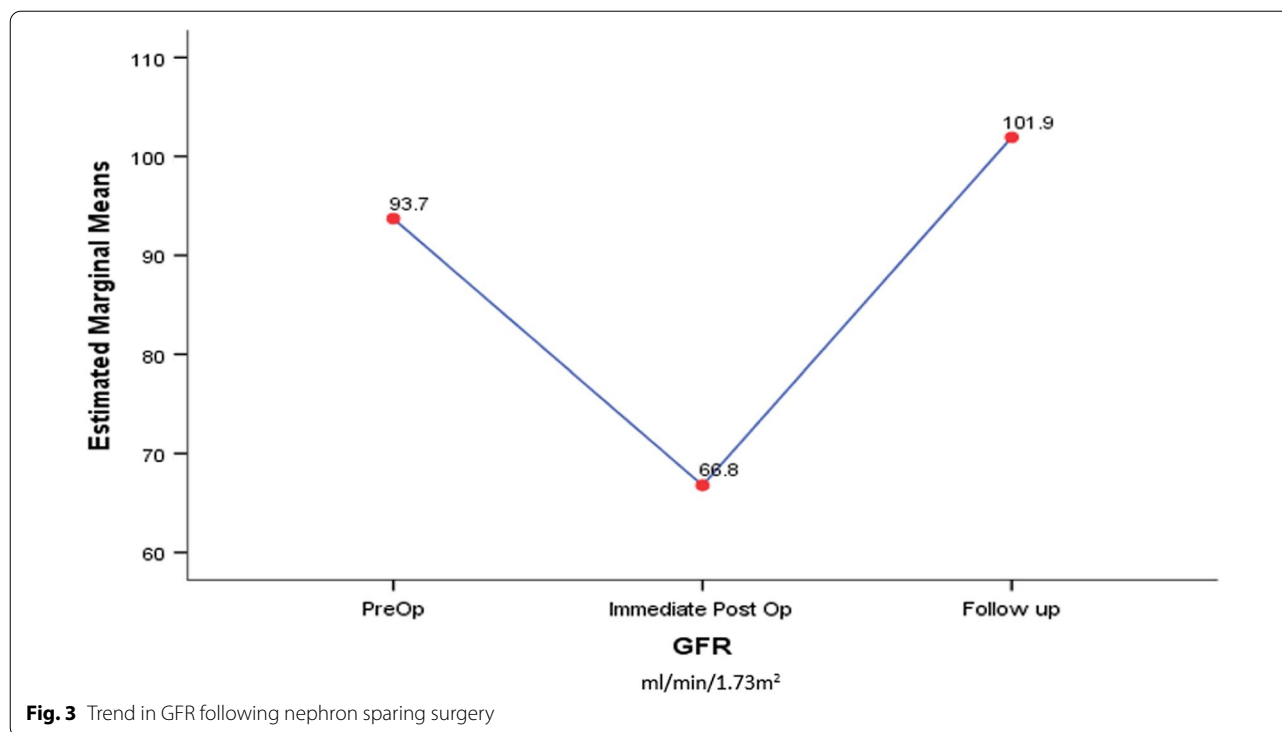
VHLS is detected commonly in the third decade. The median age at presentation shown in the literature varies from 30 to 40 years [3, 9, 10]. In the current series, the median age at presentation was 39 years (23–45). Family history is an essential factor in the clinical criteria for diagnosis and was positive in 60% of patients in this series, similar to previously reported reviews [9, 11].

The presentation of VHLS is varied. The spectrum ranges from incidentally or screen-detected to patients who present with features of cerebellar tumors, pheochromocytomas, or hematuria. If the patients were diagnosed with pheochromocytomas, adrenalectomy gets priority, followed by NSS and then excision of cerebellar tumors. In the present series, 41% of patients presented with hematuria, and a diagnosis of multifocal RCC was made.

The majority of the data on VHLS are from retrospective reviews [10, 11] and a few prospective cohorts [9]. Mutational analysis was performed in 7 of the patients in the present study, which were confirmatory of a germ-line mutation in the short arm of chromosome 3. Neumann et al. and Baghai et al. also performed the above-mentioned mutational analysis (184 and 12 patients) [9, 11].

Table 4 Review of patients who underwent adrenalectomy

Characteristics of patients who underwent adrenalectomies	Number (%)
Adrenalectomies: <i>n</i> = 10	
Total adrenalectomy	7 (70)
Cortical sparing adrenalectomy	3 (30)
Functioning adrenal tumors (<i>n</i> = 7)	6 (85)
Pre-op urinary metanephrines (mean)	2454 mcg/24 h
Post-op urinary metanephrines (mean)	< 100 mcg/24 h
CT size of tumor in cm (median/range)	5 (3–6)
No. of bilateral tumors (<i>n</i> = 7)	3 (38)



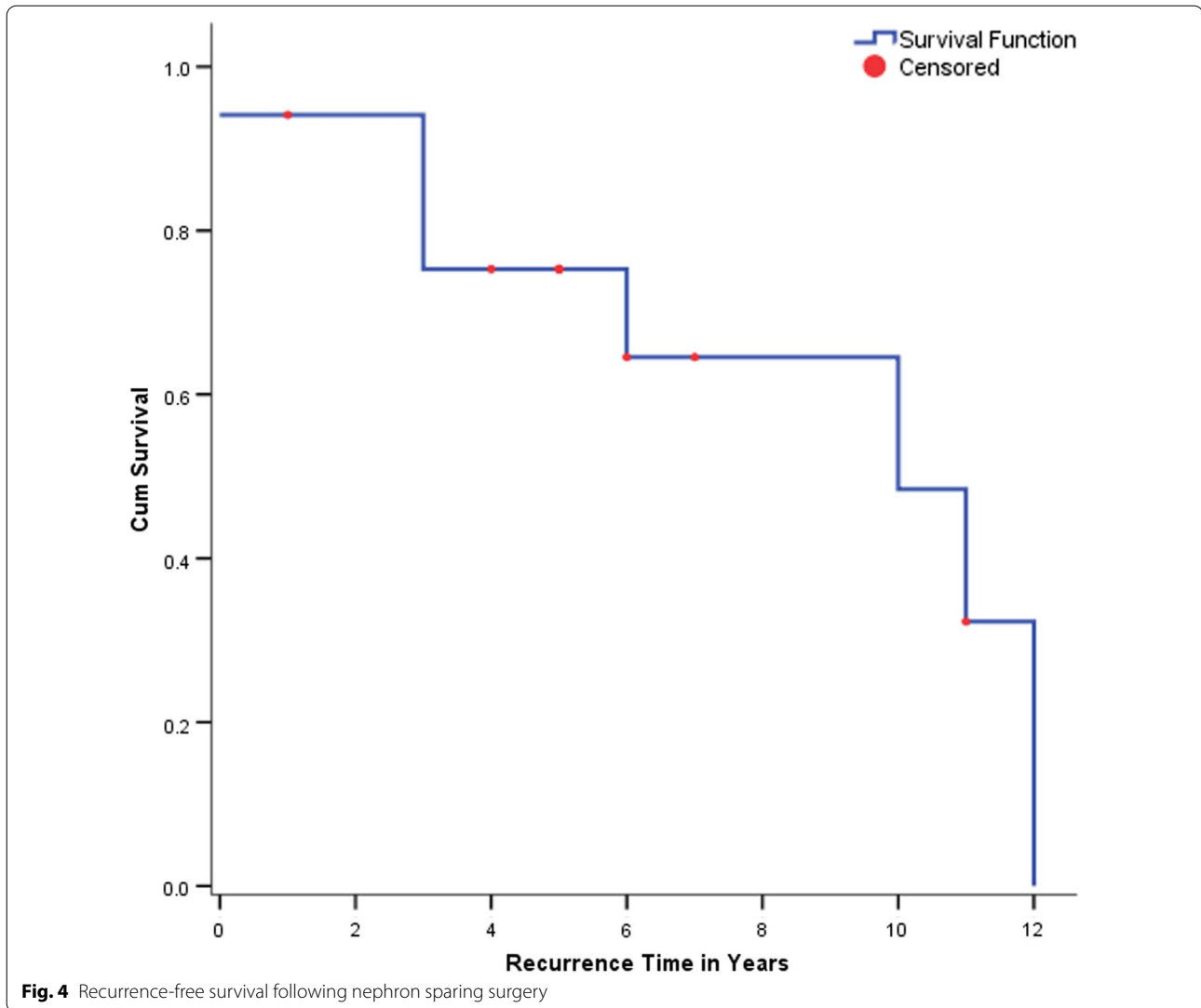
The prognosis and management of VHLS have significantly improved. Nephron sparing surgery is the current gold standard in managing multifocal RCC in patients with VHLS. We had 13 patients who underwent nephron sparing surgeries (open partial nephrectomy). The immediate postoperative renal recovery was good except in one patient who required postoperative hemodialysis for a week. Her renal functions gradually improved, and at five years follow up, it normalized. In the earlier case series published in 1992 by Novick and Stroom [3], the author reported NSS in 12 patients. Two required to be on maintenance hemodialysis, and one patient underwent a renal transplant. However, no patients required renal replacement therapy in the subsequent case reports and series by Shinohara and Jilg et al. [10, 12]. As the operative techniques of NSS and perioperative care have improved over time, the preservation of renal function can be achieved consistently, though multiple surgeries are required.

In the present series, the median follow-up was 6.5 years [2–12]. Patients with VHL who undergo NSS have a high chance of recurrence. In the current series, there were seven patients who developed local recurrence (53%). Of these, three patients (17%) required two nephron sparing surgeries. The median time of recurrence was ten years. Local recurrence has also been reported after ten years [13, 14]. Metastasis is rare [3, 9].

In this series, one patient with multifocal RCC developed a local recurrence and metastasis to the pancreas at a follow-up of 10 years. There was no mortality in the present case series. However, there was a 5–10% mortality in the earlier studies [3, 9].

Management of pheochromocytomas in patients with VHLS is also a challenge because of their bilateral occurrence. In the present series, seven patients underwent total adrenalectomies, and 3 with bilateral tumors underwent cortical sparing adrenalectomy. None of the patients developed adrenal insufficiency or crisis in the immediate postoperative period, and none required long-term steroid replacement at a median follow-up of 10 years. In a prospective cohort study by Neumann et al. [9], 184 patients with VHLS underwent adrenalectomy (30%—cortical sparing). 30% of patients developed adrenal crisis, while 13% of the patients developed iatrogenic Cushing's and needed to be on steroid replacement at a median follow-up of 8 years. However, retrospective reviews [11, 15] showed no incidence of adrenal insufficiency.

The study's limitations were that it was a retrospective review with its inherent bias and that the diagnosis in the earlier cases was based on clinical criteria only. Due to the rarity of the disease, the number of patients was few. However, the study's strengths include an excellent follow-up and only a few studies about VHLS from India.



It seems clear that oncological clearance can be optimally achieved by nephron sparing surgery. Though there is a high incidence of recurrence, a second NSS can salvage them without affecting the overall survival. Cortical sparing adrenalectomy in bilateral pheochromocytoma preserves adrenal function and avoids steroid supplementation.

5 Conclusion

The diagnosis of VHL is clinical, with mutational analysis of the 3p25 gene being confirmatory. Management requires a multidisciplinary team and a stringent follow-up. Nephron sparing surgery and cortical sparing adrenalectomy play a crucial role in achieving good oncological outcomes and in preservation of renal and adrenal function.

Abbreviations

VHLS: Von Hippel–Lindau syndrome; GFR: Glomerular filtration rate; RCC: Renal cell carcinoma; NSS: Nephron sparing surgery; MRI: Magnetic resonance imaging; CECT: Contrast-enhanced computed tomogram; PDS: Polydioxanone sodium; IRB: Institutional review board.

Acknowledgements

We would like to thank Mrs. Grace Rebecca for the statistical help offered.

Authors' contributions

PM and STJ were involved in the design of the study. STJ collected, analyzed, and interpreted the patient data regarding the oncological clearance and renal/adrenal function. PM and STJ prepared the manuscript. STJ was a major contributor in writing the manuscript. All authors read, edited, and approved the final manuscript.

Funding

None.

Availability of data and materials

The data is available if required.

Declarations

Ethics approval and consent to participate

This study was approved by the institutional ethics and review board, Christian Medical College, Vellore, TN, India (IRB Min. No. 13781 dated 27.01.2021.). Consent from participants was not required for retrospective studies according to the institutional review board and the Indian Council of Medical Research (ICMR 2017 guidelines—National Ethical Guidelines for Biomedical & Health Research involving Human Participants, 2017: Mathur Roli, Swaminathan Soumya).

Consent for publication

Not applicable.

Competing interests

The authors have no conflict of interest to declare.

Received: 17 March 2021 Accepted: 5 September 2021

Published online: 10 November 2021

References

- Von Hippel E (1904) Ueber eine sehr seltene Erkrankung der Netzhaut. Albrecht von Graefes Arch Ophthalmol 59:83–106
- Lindau A (1927) Zur Frage der Angiomatosis Retinae und Ihrer Hirncomplication. Acta Ophthalmol 4(1):193–226
- Novick AC, Stroom SB (1992) Long-term follow-up after nephron sparing surgery for renal cell carcinoma in Von Hippel–Lindau disease. J Urol 147(6):1488–1490
- Shuin T, Yamasaki I, Tamura K, Okuda H, Furihata M, Ashida S (2006) Von Hippel–Lindau disease: molecular pathological basis, clinical criteria, genetic testing, clinical features of tumors and treatment. Jpn J Clin Oncol 36(6):337–343
- Ben-Skowronek I, Kozaczuk S (2015) Von Hippel–Lindau syndrome. Horm Res Paediatr 84(3):145–152
- Čtvrtník F, Koranda P, Schovánek J, Škarda J, Hartmann I, Tüdös Z (2018) Current diagnostic imaging of pheochromocytomas and implications for therapeutic strategy. Exp Ther Med 15(4):3151–3160
- Roizen MF, Hunt TK, Beaupre PN, Kremer P, Firmin R, Chang CN et al (1983) The effect of alpha-adrenergic blockade on cardiac performance and tissue oxygen delivery during excision of pheochromocytoma. Surgery 94(6):941–945
- Varshney N, Kebede AA, Owusu-Dapaah H, Lather J, Kaushik M, Bhullar JS (2017) A review of Von Hippel–Lindau syndrome. J Kidney Cancer VHL 4(3):20–29
- Neumann HPH, Tsoy U, Bancos I, Amodru V, Walz MK, Tirosh A et al (2019) Comparison of pheochromocytoma-specific morbidity and mortality among adults with bilateral pheochromocytomas undergoing total adrenalectomy vs cortical-sparing adrenalectomy. JAMA Netw Open 2(8):e198898
- Jilg CA, Neumann HPH, Gläsker S, Schäfer O, Leiber C, Ardelit PU et al (2012) Nephron sparing surgery in Von Hippel–Lindau associated renal cell carcinoma: clinicopathological long-term follow-up. Fam Cancer 11(3):387–394
- Baghai M, Thompson GB, Young WF, Grant CS, Michels VV, van Heerden JA (2002) Pheochromocytomas and paragangliomas in Von Hippel–Lindau disease: a role for laparoscopic and cortical-sparing surgery. Arch Surg 137(6):682–689
- Shinohara N, Nonomura K, Harabayashi T, Togashi M, Nagamori S, Koyanagi T (1995) Nephron sparing surgery for renal cell carcinoma in Von Hippel–Lindau disease. J Urol 154(6):2016–2019
- Ploussard G, Droupy S, Ferlicot S, Ples R, Rocher L, Richard S et al (2007) Local recurrence after nephron-sparing surgery in Von Hippel–Lindau disease. Urology 70(3):435–439
- Fujita N, Mikami J, Murasawa H, Okamoto A, Imai A, Hatakeyama S et al (2013) Local recurrence of pheochromocytoma associated with Von Hippel–Lindau disease 26 years after bilateral adrenalectomy: a case report. Hinyokika Kyo 59(7):427–430
- Benhammou JN, Boris RS, Pacak K, Pinto PA, Linehan WM, Bratslavsky G (2010) Functional and oncologic outcomes of partial adrenalectomy for pheochromocytoma in VHL patients after at least 5 years of follow up. J Urol 184(5):1855–1859

Publisher's Note

Springer Nature remains neutral with regard to jurisdictional claims in published maps and institutional affiliations.

Submit your manuscript to a SpringerOpen® journal and benefit from:

- Convenient online submission
- Rigorous peer review
- Open access: articles freely available online
- High visibility within the field
- Retaining the copyright to your article

Submit your next manuscript at ► [springeropen.com](https://www.springeropen.com)