Periasamy *et al. African Journal of Urology* (2024) 30:15
https://doi.org/10.1186/s12301-024-00418-1

African Journal of Urology

REVIEW

Open Access

Primary renal leiomyosarcoma in adult patients: a systematic review and individual patient data analysis

Kannan Periasamy[1], Treshita Dey[1*], Shikha Goyal[1], Renu Madan[1], Santosh Kumar[2], Sudheer Kumar Devana[2], Thiraviyam Elumalai[3], Prashanth Giridhar[4], Sushmita Ghoshal[1], Rakesh Kapoor[1] and Chandan K. Das[5]

Abstract

Purpose The optimal management of primary renal leiomyosarcomas is unknown owing to its rarity and minimal available information about their primary, adjuvant treatment and clinical outcomes. This study systematically reviews treatment evidence and effects in terms of survival for leiomyosarcomas arising primarily from kidney, renal pelvis and renal vessels.

Method PubMed and Embase databases were searched from inception to March 2023, with manual searches of reference lists. Two investigators independently reviewed the studies reporting management and survival outcomes of renal leiomyosarcomas.

Results A total of 85 publications met inclusion criteria, reporting on 188 cases. The median age was 55.5 years, predominantly female [52.7%]. Pain was the most common presenting symptom [41.5%], and most tumors were high grade [45.8%]. Complete surgical resection with negative margins forms definitive treatment. The median disease-free survival and overall survival (OS) for all reviewed patients were 24 months [95%CI 4.1–43.9] and 42 months [95%CI 32.5–51.4], respectively. The OS of 1 year, 2 year, 3 year and 5 year was 78.8%, 64.4%, 53.8% and 38.9%, respectively. On univariate analysis, favorable factors for OS included tumor size ≤ 5 cm, low-grade histology, tumors of renal vascular origin and non-metastatic disease at presentation. Neoadjuvant or adjuvant treatment with either radiotherapy or chemotherapy has been shown to improve OS (NR vs. 36 months, $p < 0.001$), especially for high-grade tumors > 5 cm in size.

Conclusion Radical nephrectomy with en bloc tumor resection with negative margins forms the mainstay of treatment for renal leiomyosarcomas. Adjuvant radiotherapy or chemotherapy appears to improve OS. To validate this treatment strategy, prospective multicentric efforts are required to acquire reliable data from randomized trials.

Keywords Renal leiomyosarcoma, Systematic review, Renal sarcoma, Survival

*Correspondence:
Treshita Dey
treshita.dey@gmail.com
Full list of author information is available at the end of the article

Springer Open

© The Author(s) 2024. **Open Access** This article is licensed under a Creative Commons Attribution 4.0 International License, which permits use, sharing, adaptation, distribution and reproduction in any medium or format, as long as you give appropriate credit to the original author(s) and the source, provide a link to the Creative Commons licence, and indicate if changes were made. The images or other third party material in this article are included in the article's Creative Commons licence, unless indicated otherwise in a credit line to the material. If material is not included in the article's Creative Commons licence and your intended use is not permitted by statutory regulation or exceeds the permitted use, you will need to obtain permission directly from the copyright holder. To view a copy of this licence, visit http://creativecommons.org/licenses/by/4.0/.

1 Introduction

Renal leiomyosarcomas are rare malignant tumors arising from smooth muscle found in inner layer of renal capsule, walls of stellate veins that drain superficial renal cortex, renal pelvis and renal blood vessels. Though they account for 50–60% of renal sarcomas, they constitute only < 1.5% of primary renal malignancies [1–3]. Being a rare entity, publications on renal leiomyosarcoma (LMS) are primarily either case reports or part of case series on renal sarcomas [4–6].

Owing to its rarity, there is little information available with limited understanding regarding their treatment, recurrence, metastasis and long-term survival outcomes. Hence, we proposed to perform systematic review and individual patient data analysis of all published cases to summarize existing evidence for primary and adjuvant treatment. A systematic review of case reports and series cannot establish the standard of care for managing renal LMS. However, it can identify significant associations and generate hypotheses for future studies. Our primary objective is to determine clinical and pathological characteristics, patterns of care and long-term survival outcomes of such patients.

2 Methods

2.1 Literature search and inclusion criteria

This systematic review with meta-analysis was constructed in accordance with Preferred Reporting Items for Systematic reviews and Meta-analysis (PRISMA) framework. Electronic databases such as PubMed and EMBASE were searched from inception to March 2023 to identify studies published in English language on renal LMS in adults > 18 years. The search strategy was carried out with the National Library of Medicine's Medical Subject Heading (MeSH) terms like 'leiomyosarcoma,' 'primary leiomyosarcoma,' 'kidney,' 'renal,' 'renal pelvis' with different Boolean operators (and/or). A manual search of reference lists of included articles was also performed to make sure there was no additional case unidentified from the primary search. Only studies in English language were included. Cases were included only if patients had LMS arising primarily from kidney, renal pelvis and renal vessels and outcomes at last follow-up were mentioned. Recurrent LMS, LMS arising in renal transplants and inferior vena cava leiomyosarcomas were excluded. Also, non-human studies, review articles, systematic review or meta-analysis was excluded. Only case reports and case series were included which had individual patient details. The PICO (patient-intervention-comparison-outcome) questionnaire is attached in Table 1.

2.2 Study selection

Two investigators independently screened search results obtained through various databases for eligible publications by title and abstract screening after removing duplicates. Next, full text of eligible publications was reviewed for data synthesis and analysis. When a discrepancy was observed between the investigators, the said abstract was reviewed by both in collaboration.

2.3 Risk of bias

Based on the type of study included, risk of bias analysis was done. The Joanna Briggs Inventory (JBI) was used for the risk of bias analysis for case reports and National Institute of Health (NIH) quality assessment tool for case series [7, 8].

2.4 Data extraction and quality assessment

For each article, we extracted data on age, gender, clinical presentation, tumor size, grade, type of surgery, details of adjuvant treatment, if any, and outcomes in terms of patterns of relapse, disease status and survival, at the last follow-up.

2.5 Data analysis

The extracted data were tabulated in Statistical Package for Social Sciences (SPSS) version 23. Categorical variables were represented with percentages, median with interquartile range for continuous variables. Survival analysis was done using Kaplan–Meier method. Log-rank test was used to determine factors affecting survival, and p-value < 0.05 was considered significant. Univariate Cox regression analysis was used to determine the hazard ratios, and if they were significant, multivariate analyzed was done. Missing data were censored from the various sub-group analysis.

3 Results

Our search strategy yielded 1256 articles, of which 966 abstracts were screened after excluding duplicate articles. Based on exclusion criteria, 797 articles were excluded yielding 169 publications after add-ons from reference lists. Finally, 85 articles with 188 patient records were considered for quantitative analysis [Fig. 1, Table 2].

Table 1 PICO questionnaire

Patient/problem	Intervention	Comparison	Outcome
Patients with primary renal LMS	surgery or adjuvant treatment	None	Improve disease outcomes

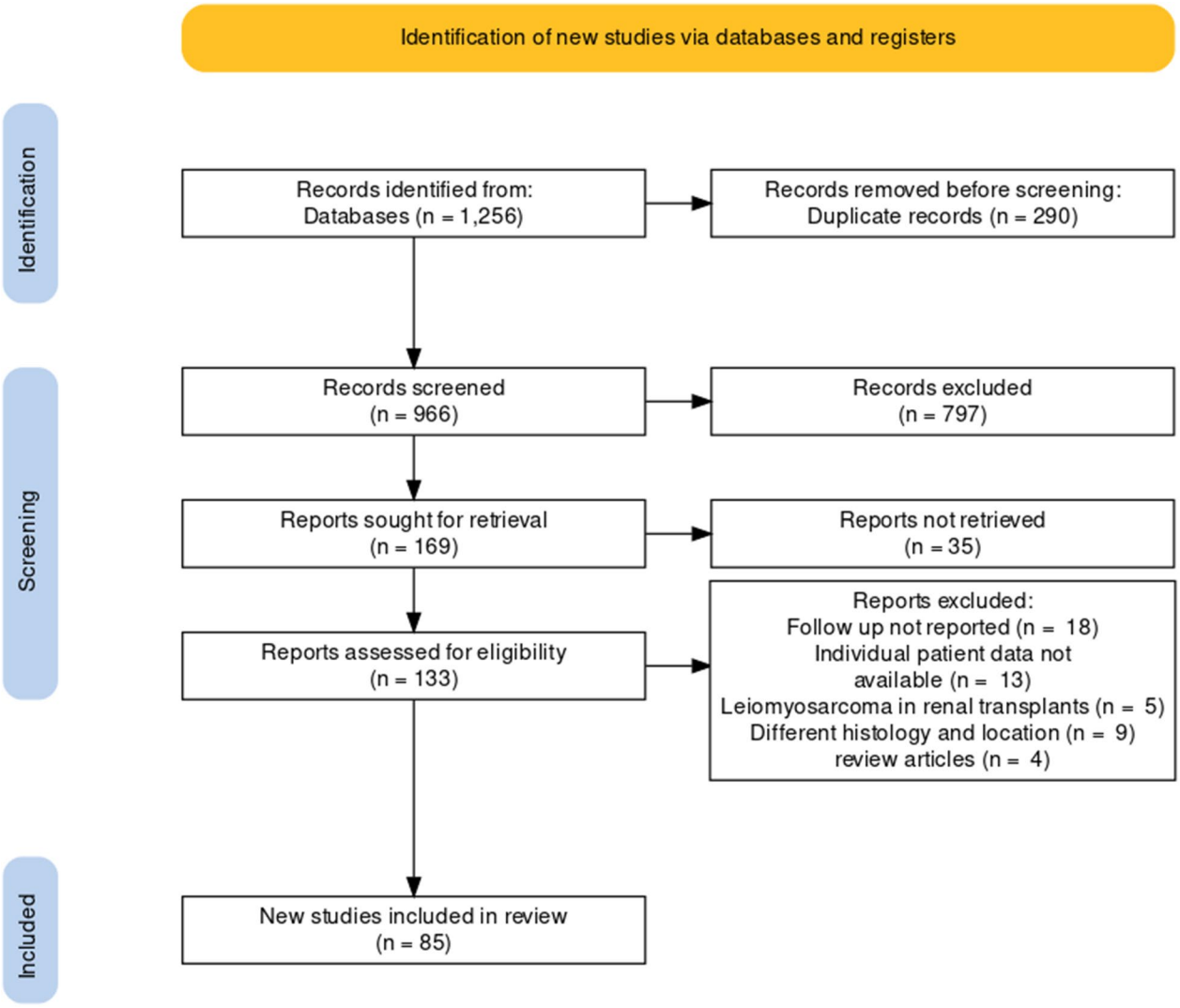

Fig. 1 Prisma flowchart

3.1 Patient demographics

Of 188 patients, 52.7% were females. The median age was 55.5 years, and 58% were symptomatic at presentation. The most common presenting symptom was pain (41.5%), followed by palpable mass (19.7%) and hematuria (13%). Primarily they originated from renal parenchyma, renal vessels (18.6%) and renal pelvis (7.4%)—over 50% patients presented with tumor size > 5 cm. Only 8.5% were metastatic at presentation (Table 3).

3.2 Treatment

The treatment characteristics are reported in Table 4. The primary modality of treatment was surgery (87.2%). Three-fourths underwent radical resection, only 3% underwent partial resection, while 1.6% underwent surgical debulking or biopsy. Only 23 patients received radiotherapy (9 palliative), and 28 received chemotherapy (15 palliative).

Table 2 Risk of bias assessment of included studies

Study	Q1		Q2		Q3		Q4		Q5		Q6		Q7		Q8		Overall appraisal	
	R1	R2	R1	R2	R1	R2	R1	R2	R1	R2	R1	R2	R1	R2	R1	R2	R1	R2
A. Assessment of case reports by JBI critical appraisal checklist for case reports (n = 72)																		
Aguilar et al. [18]	Y	Y	Y	Y	Y	Y	Y	Y	Y	Y	Y	Y	NA	NA	Y	Y	I	I
Aiken et al. [19]	Y	Y	Y	N	Y	Y	Y	Y	Y	Y	Y	Y	NA	NA	Y	Y	I	I
Anoshkin et al. [20]	Y	Y	Y	Y	Y	Y	Y	Y	Y	Y	N	Y	NA	NA	Y	Y	I	I
Appell et al. [21]	Y	Y	Y	Y	Y	N	Y	Y	Y	Y	Y	Y	NA	NA	Y	Y	I	I
Azizun-Nisa et al. [22]	Y	Y	Y	Y	Y	Y	Y	Y	Y	Y	Y	Y	NA	NA	Y	N	I	I
Ball et al. [23]	Y	Y	Y	Y	Y	Y	Y	Y	N	Y	Y	Y	NA	NA	Y	Y	I	I
Bazaz-malik et al. [24]	Y	Y	Y	Y	Y	Y	Y	Y	Y	Y	Y	Y	NA	NA	Y	Y	I	I
Beccia et al. [25]	Y	Y	Y	Y	Y	Y	Y	Y	Y	Y	Y	Y	NA	NA	N	Y	I	I
Bhathena et al. [26]	Y	Y	Y	Y	Y	Y	N	Y	Y	Y	Y	Y	NA	NA	Y	Y	I	I
Chatlani et al. [27]	Y	Y	Y	Y	Y	Y	Y	Y	Y	Y	Y	Y	NA	NA	Y	Y	I	I
Cho et al. [28]	Y	Y	Y	Y	Y	Y	Y	Y	Y	Y	Y	Y	NA	NA	Y	Y	I	I
Chougule et al. [29]	Y	Y	Y	Y	Y	Y	Y	Y	Y	Y	Y	Y	NA	NA	Y	Y	I	I
Choudhury et al. [12]	Y	Y	N	Y	Y	Y	Y	Y	Y	Y	Y	Y	NA	NA	Y	Y	I	I
Ciriaco et al. [30]	Y	Y	Y	Y	Y	Y	Y	Y	Y	Y	Y	Y	NA	NA	Y	Y	I	I
Cocuzza et al. [31]	Y	Y	Y	Y	Y	Y	Y	Y	Y	Y	Y	Y	NA	NA	N	Y	I	I
Davis et al. [32]	Y	Y	Y	Y	Y	Y	Y	N	Y	Y	Y	Y	NA	NA	Y	Y	I	I
Demir et al. [33]	Y	Y	Y	Y	Y	Y	Y	Y	Y	Y	Y	Y	NA	NA	Y	N	I	I
Dhamne et al. [34]	Y	Y	Y	N	Y	Y	Y	Y	Y	Y	Y	Y	NA	NA	Y	Y	I	I
Dhawan et al. [11]	Y	Y	Y	Y	Y	Y	Y	N	Y	Y	Y	Y	NA	NA	Y	Y	I	I
Dominici et al. [35]	Y	Y	Y	Y	Y	Y	Y	Y	Y	Y	Y	Y	NA	NA	Y	Y	I	I
Douma et al. [36]	Y	Y	Y	Y	Y	N	Y	Y	Y	Y	Y	Y	NA	NA	Y	Y	I	I
Ellouze et al. [37]	Y	Y	Y	Y	Y	Y	Y	Y	Y	Y	Y	Y	NA	NA	Y	Y	I	I
Fernandez et al. [38]	Y	Y	N	Y	Y	Y	Y	Y	Y	Y	Y	Y	NA	NA	N	Y	I	I
Grasso et al. [39]	Y	Y	Y	Y	Y	Y	N	Y	Y	Y	Y	Y	NA	NA	Y	Y	I	I
Gierson et al. [40]	Y	Y	Y	Y	Y	Y	Y	Y	Y	Y	Y	Y	NA	NA	Y	N	I	I
Gill et al. [41]	Y	Y	Y	Y	Y	Y	Y	Y	Y	Y	Y	N	NA	NA	Y	Y	I	I
Grignon et al. [42]	Y	Y	Y	Y	Y	Y	Y	Y	Y	N	Y	Y	NA	NA	N	Y	I	I
Helmbrecht et al. [43]	Y	Y	Y	Y	N	Y	Y	Y	Y	Y	Y	Y	NA	NA	Y	Y	I	I
Herman et al. [44]	Y	Y	Y	Y	Y	Y	Y	Y	Y	Y	Y	Y	NA	NA	Y	N	I	I
Higbee et al. [45]	Y	Y	Y	Y	Y	Y	Y	N	Y	Y	Y	Y	NA	NA	Y	Y	I	I
Imao et al. [46]	Y	Y	Y	Y	Y	N	Y	Y	Y	Y	Y	Y	NA	NA	Y	Y	I	I
Inoue et al. [47]	Y	Y	Y	Y	Y	Y	Y	Y	Y	N	Y	Y	NA	NA	Y	Y	I	I
Islam et al. [48]	Y	Y	Y	Y	Y	Y	Y	Y	Y	Y	Y	Y	NA	NA	N	Y	I	I
Jenkins et al. [49]	Y	Y	Y	Y	Y	Y	Y	Y	Y	Y	Y	Y	NA	NA	Y	Y	I	I
Kartsanis et al. [50]	Y	Y	Y	Y	Y	N	Y	Y	Y	Y	Y	Y	NA	NA	Y	Y	I	I
Kaufman et al. [51]	Y	Y	Y	Y	Y	Y	Y	Y	Y	Y	Y	Y	NA	NA	Y	Y	I	I
Kaushik et al. [52]	Y	Y	N	Y	Y	Y	Y	Y	Y	Y	Y	Y	NA	NA	Y	Y	I	I
Krech et al. [53]	Y	Y	Y	Y	Y	Y	Y	Y	Y	Y	Y	Y	NA	NA	Y	N	I	I
Kretschmer et al. [54]	Y	Y	Y	Y	Y	N	Y	Y	Y	Y	Y	Y	NA	NA	Y	Y	I	I
Kumar et al. [55]	Y	Y	Y	Y	Y	Y	Y	Y	Y	Y	Y	Y	NA	NA	Y	Y	I	I
Lazarus et al. [56]	Y	Y	Y	Y	N	Y	Y	Y	Y	Y	Y	Y	NA	NA	Y	Y	I	I
Lea Thomas et al. [57]	Y	Y	Y	Y	Y	Y	Y	N	Y	Y	Y	Y	NA	NA	Y	Y	I	I
Leinwand et al. [58]	Y	Y	Y	Y	Y	Y	N	Y	Y	Y	Y	Y	NA	NA	Y	Y	I	I
Loertzer et al. [59]	Y	Y	Y	Y	Y	Y	Y	Y	Y	Y	Y	Y	NA	NA	Y	Y	I	I
Loomis et al. [60]	Y	Y	Y	Y	Y	Y	Y	N	Y	Y	Y	Y	NA	NA	Y	Y	I	I
Lopez-varela et al. [61]	Y	Y	Y	Y	Y	Y	Y	Y	Y	Y	Y	Y	NA	NA	Y	N	I	I

Table 2 (continued)

Study	Q1		Q2		Q3		Q4		Q5		Q6		Q7		Q8		Overall appraisal	
	R1	R2	R1	R2	R1	R2	R1	R2	R1	R2	R1	R2	R1	R2	R1	R2	R1	R2
Maeda et al. [62]	Y	Y	Y	Y	N	Y	Y	Y	Y	Y	Y	Y	NA	NA	Y	Y	I	I
Makis et al. [63]	Y	Y	Y	Y	Y	Y	Y	Y	Y	Y	Y	Y	NA	NA	N	Y	I	I
Martin et al. [64]	Y	Y	Y	Y	Y	Y	Y	Y	Y	Y	Y	Y	NA	NA	Y	Y	I	I
Minami et al. [65]	Y	Y	Y	Y	Y	N	Y	Y	Y	Y	Y	Y	NA	NA	Y	Y	I	I
Montgomery et al. [66]	Y	Y	Y	Y	Y	Y	Y	Y	Y	Y	N	Y	NA	NA	Y	Y	I	I
Moudouni et al. [67]	Y	Y	Y	Y	Y	Y	Y	Y	Y	Y	Y	Y	NA	NA	Y	Y	I	I
Moazzam et al. [13]	Y	Y	Y	Y	Y	Y	Y	Y	Y	Y	Y	Y	NA	NA	Y	Y	I	I
Niceta et al. [68]	Y	Y	Y	Y	Y	Y	Y	Y	Y	Y	Y	Y	NA	NA	Y	Y	I	I
Narula et al. [69]	Y	Y	N	Y	Y	Y	Y	Y	Y	Y	N	Y	NA	NA	Y	Y	I	I
Ojha et al. [70]	Y	Y	Y	Y	Y	Y	N	Y	Y	Y	Y	Y	NA	NA	Y	Y	I	I
Pelton et al. [71]	Y	Y	Y	Y	Y	Y	Y	Y	Y	Y	Y	Y	NA	NA	Y	Y	I	I
Phoa et al. [72]	Y	Y	Y	Y	Y	Y	Y	Y	Y	N	Y	Y	NA	NA	Y	Y	I	I
Polsky et al. [73]	Y	Y	Y	N	Y	Y	Y	Y	Y	Y	Y	Y	NA	NA	Y	Y	I	I
Rakowsky et al. [74]	Y	Y	Y	Y	Y	Y	Y	Y	Y	Y	N	Y	NA	NA	Y	N	I	I
Radhakrishnan et al. [75]	Y	Y	Y	Y	Y	N	Y	Y	Y	Y	Y	Y	NA	NA	Y	Y	I	I
Raghavendran et al. [76]	Y	Y	Y	Y	Y	Y	Y	Y	N	Y	Y	Y	NA	NA	Y	N	I	I
Roy et al. [77]	Y	Y	Y	Y	N	Y	Y	Y	Y	Y	Y	Y	NA	NA	Y	Y	I	I
Selli et al. [78]	Y	Y	Y	Y	Y	Y	Y	Y	Y	Y	Y	Y	NA	NA	N	Y	I	I
Sharma et al. [79]	Y	Y	Y	Y	Y	N	Y	Y	Y	Y	Y	Y	NA	NA	Y	Y	I	I
Stringer et al. [80]	Y	Y	Y	Y	Y	Y	N	Y	Y	Y	Y	Y	NA	NA	Y	Y	I	I
Tanaka et al. [81]	Y	Y	Y	Y	Y	Y	Y	Y	Y	Y	Y	Y	NA	NA	Y	Y	I	I
Tolia et al. [82]	Y	Y	Y	Y	Y	Y	Y	N	Y	Y	Y	Y	NA	NA	Y	Y	I	I
Usawachintachit et al. [83]	Y	Y	Y	Y	Y	Y	Y	Y	Y	Y	Y	Y	NA	NA	Y	Y	I	I
van den Berg et al. [84]	Y	Y	Y	Y	Y	N	Y	Y	Y	Y	Y	Y	NA	NA	Y	Y	I	I
Vos et al. [85]	Y	Y	Y	Y	Y	Y	Y	Y	Y	Y	N	Y	NA	NA	N	Y	I	I
Yokose et al. [86]	Y	Y	Y	Y	Y	Y	Y	Y	Y	Y	Y	Y	NA	NA	Y	Y	I	I

Study	Q1		Q2		Q3		Q4		Q5		Q6		Q7		Q8		Q9		Assessment	
	R1	R2	R1	R2	R1	R2	R1	R2	R1	R2	R1	R2	R1	R2	R1	R2	R1	R2	R1	R2
B. Assessment of case series by NIH quality assessment tool for case series ($n=13$)																				
Brandes et al. [87]	Y	Y	Y	Y	NA	NA	Y	Y	Y	Y	NA	NA	NA	NA	NA	NA	Y	Y	Fair	Fair
Cong et al. [88]	Y	Y	Y	Y	NA	NA	Y	Y	Y	Y	NA	NA	NA	NA	NA	NA	Y	Y	Fair	Fair
Deyrup et al. [5]	Y	Y	Y	Y	NA	NA	Y	Y	Y	Y	NA	NA	NA	NA	NA	NA	N	Y	Fair	Fair
Gupta et al. [89]	Y	Y	Y	Y	NA	NA	Y	Y	Y	Y	NA	NA	NA	NA	NA	NA	Y	Y	Fair	Fair
Huang et al. [90]	Y	Y	Y	Y	NA	NA	Y	Y	Y	Y	NA	NA	NA	NA	NA	NA	Y	Y	Fair	Fair
Maturen et al. [91]	Y	Y	Y	Y	NA	NA	Y	Y	Y	Y	NA	NA	NA	NA	NA	NA	Y	Y	Fair	Fair
Miller et al. [4]	Y	Y	Y	Y	NA	NA	Y	Y	Y	Y	NA	NA	NA	NA	NA	NA	N	Y	Fair	Fair
Mucci et al. [92]	Y	Y	Y	Y	NA	NA	Y	Y	Y	Y	NA	NA	NA	NA	NA	NA	Y	Y	Fair	Fair
Novak et al. [6]	Y	Y	Y	Y	NA	NA	Y	Y	Y	Y	NA	NA	NA	NA	NA	NA	Y	Y	Fair	Fair
Ozturk et al. [93]	Y	Y	Y	Y	NA	NA	Y	Y	Y	Y	NA	NA	NA	NA	NA	NA	Y	Y	Fair	Fair
Srinivas et al. [94]	Y	Y	Y	Y	NA	NA	Y	Y	Y	Y	NA	NA	NA	NA	NA	NA	N	Y	Fair	Fair
Vogelzang et al. [95]	Y	Y	Y	Y	NA	NA	Y	Y	Y	Y	NA	NA	NA	NA	NA	NA	Y	Y	Fair	Fair
Vuruskan et al. [96]	Y	Y	Y	Y	NA	NA	Y	Y	Y	Y	NA	NA	NA	NA	NA	NA	Y	Y	Fair	Fair

I: Included, Y: Yes, N: No, NA: Not applicable

Table 3 Patient and tumor characteristics (n = 188)

Characteristics	Frequency
Age (n = 180)	Mean ± SD: 54.81 ± 14.46 Median 55.5 (IQR 44.25–77) Range: 16–93
Gender (n = 170)	
Male	71 (37.8%)
Female	99 (52.7%)
Symptoms at presentation (n = 122)	
Symptomatic	109 (58%)
Asymptomatic	13 (6.9%)
Site of origin (n = 181)	
Kidney	132 (70.2%)
Pelvis	14 (7.4%)
Renal artery	1 (0.5%)
Renal vein	34 (18.1%)
Laterality (n = 130)	
Right	62 (33%)
Left	67 (35.6%)
Bilateral	1 (0.5%)
Tumor size (n = 137)	
≤ 5 cm	26 (13.8%)
6-10 cm	57 (30.3%)
> 10 cm	54 (28.7%)
Grade (n = 105)	
Low	19 (10.1%)
Intermediate	43 (22.9%)
High	43 (22.9%)
Metastasis at presentation (n = 162)	
Yes	16 (8.5%)
No	146 (77.7%)

Table 4 Treatment characteristics (*n* = 188)

Characteristics	Frequency
Surgery for treatment	
Yes	164 (87.2%)
No	4 (2.1%)
Radiotherapy	
Neo-adjuvant	3 (1.6%)
Adjuvant	11 (5.9%)
Palliative	9 (4.8%)
Chemotherapy	
Neo-adjuvant	3 (1.6%)
Adjuvant	10 (5.3%)
Palliative	15 (8%)
Management	
Surgery	142 (75.5%)
Surgery + RT	9 (4.8%)
Surgery + chemotherapy	9 (4.8%)
Surgery + RT + chemotherapy	4 (2.1%)
No treatment	4 (2.1%)

3.3 Patterns of relapse

Sixty-two (33%) had disease relapse after primary treatment. One-fourth (47) of the patients had distant relapse. Seven patients (3.7%) had both local and distant relapse, whereas three (1.6%) patients had only local relapse. Among distant relapses, lung metastasis was most common (16.5%), followed closely by liver (11.2%) and bones (6.4%).

3.4 Survival

After median follow-up of 19 months (interquartile range (IQR) 9–45 months), 70 (37%) were alive without any evidence of disease and 26 (13.8%) were alive with disease; 79 (42%) died of disease itself, while 13 (7%) died of other causes. The median disease-free survival (DFS) was 24 months [95% confidence interval (CI) 4.1–43.9 months]. The DFS rates at 1 year, 2 year, 3 year and 5 year were 65.3%, 49.4%, 43.6% and 33%, respectively. The median overall survival (OS) was 42 months [95% CI 32.5–51.4 months]. The survival rates at 1 year, 2 year, 3 year and 5 year were 78.8%, 64.4%, 53.8% and 38.9%, respectively. Kaplan–Meier curves for DFS and OS are shown in Fig. 2.

3.5 Factors affecting survival

Favorable prognosis with better OS (Fig. 3) was noted in female (54 vs. 31 months, $p = 0.077$) gender, patients having tumor size ≤ 5 cm (72 vs. 48 months, $p = 0.056$), renal vascular origin (72 vs. 36 months, $p = 0.016$), low-grade (138 vs. 48 vs. 19 months, $p < 0.001$) tumors and non-metastatic disease (45 vs. 12 months, $p < 0.001$). While univariate analysis demonstrated improved DFS with female gender (60 vs. 9 months, $p = 0.007$) and non-metastatic disease [36 vs. 3 months, $p = 0.001$], multivariate analysis showed significance for none (Table 5).

Patients who received multimodality treatment had significantly better survival than surgery alone (NR vs. 36 months, $p < 0.001$), while those without intervention had median survival of 2 months. The extent of surgery significantly impacted survival; those with partial or radical nephrectomy had better median OS (36 and 44 months) than those with debulking or biopsy only (3 months). Surgical margin status significantly impacted prognosis; positive margin status had 3-month survival, whereas median OS was not yet reached for those with negative margins ($p < 0.001$). Better survival was also noted in asymptomatic patients compared to those who were symptomatic at presentation (38 vs. 44 months, $p = 0.898$). However, on multivariate analysis, none significantly impacted survival.

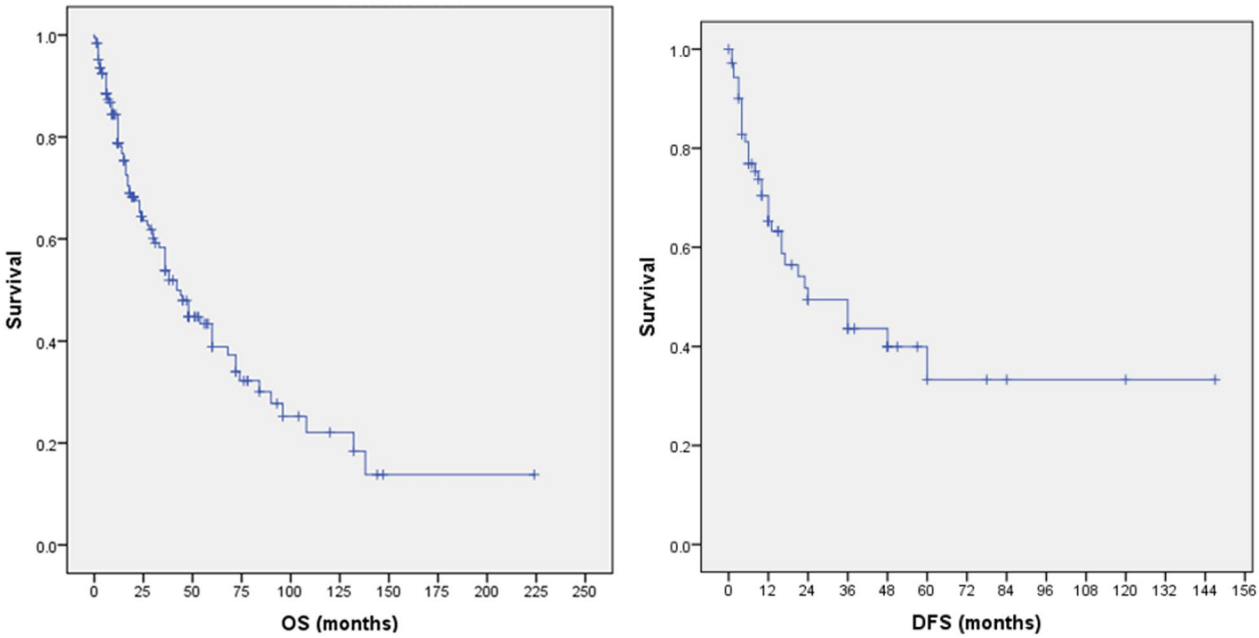

Fig. 2 Kaplan–Meier curves depicting OS and DFS for all reviewed patients

Adding radiotherapy or chemotherapy in neo-adjuvant or adjuvant settings improved survival, especially in tumor > 5 cm and high-grade tumors. The 2-year survival in patients receiving surgery only was 89.3% (≤ 5 cm) and 58.4%(> 5 cm), while those receiving radiotherapy/chemotherapy was better, 100% (≤ 5 cm) and 100% (> 5 cm). Similar results were also observed with addition of chemoradiotherapy after surgery with regard to tumor grade: 88.9% (low grade with surgery only), 100% (low grade with radio-chemotherapy) vs 49.4% (high or intermediate grade with surgery only), 80% (high or intermediate grade with chemoradiotherapy).

4 Discussion

Soft tissue sarcomas (STS) account for < 1% of all cancers, with extremities being most common site. There are several histological types of STS, including LMS and liposarcoma. The genitourinary tract represents 2.1% of soft tissue sarcomas (STS), with renal being second most common location after para-testicular region. Primary renal LMS comprise 50–60% of all renal sarcomas and are extremely rare. They constitute 0.12% of all renal malignancies [1, 2, 9, 10]. Renal LMS originate from renal capsule, smooth muscles in renal pelvis or renal vessels. Preoperative diagnosis of these tumors is almost impossible because of non-specific clinical symptoms and radiological findings. Pathologically, differentiation from sarcomatoid renal cell carcinoma is essential as there is prognostic difference. Desmin positivity confirms diagnosis of LMS as sarcomatoid carcinomas may express smooth muscle actin (SMA) [11, 12].

The present analysis revealed that the median age at presentation for renal LMS was 55.5 years with predilection for female gender unlike other STS where there is male preponderance with male to female ratio of 1.4:1. The clinical presentation included abdominal pain (41.5%), abdominal mass, hematuria or combination, thus mimicking other renal tumors. Emergency presentations with spontaneous rupture have been reported in a few [13]. More than half of patients had tumor size > 5 cm at diagnosis, explaining that renal sarcomas expand and grow large due to lack of natural barriers. Further, in this study, we found that approximately one-third of patients relapse after primary treatment at median follow-up of 19 months, with distant recurrence accounting for nearly 50% relapses. The most common sites of metastases in order of decreasing frequency include lungs, liver and bones, exemplifying that renal LMS frequently spreads to distant areas via hematogenous route.

The present study demonstrated median survival of 42 months for all reviewed renal LMS patients. The 3-year and 5-year survival was estimated to be 53.8% and 38.9%, respectively, similar to 5-year survival reported by Lee et al. in their study on urological STS [14]. They also reported 5-year survival rate of 73%, 44% and 82% for bladder, prostate and retroperitoneal sarcomas, respectively. Thus, renal sarcomas have poorer prognosis when compared to other urinary tract sarcomas. To our

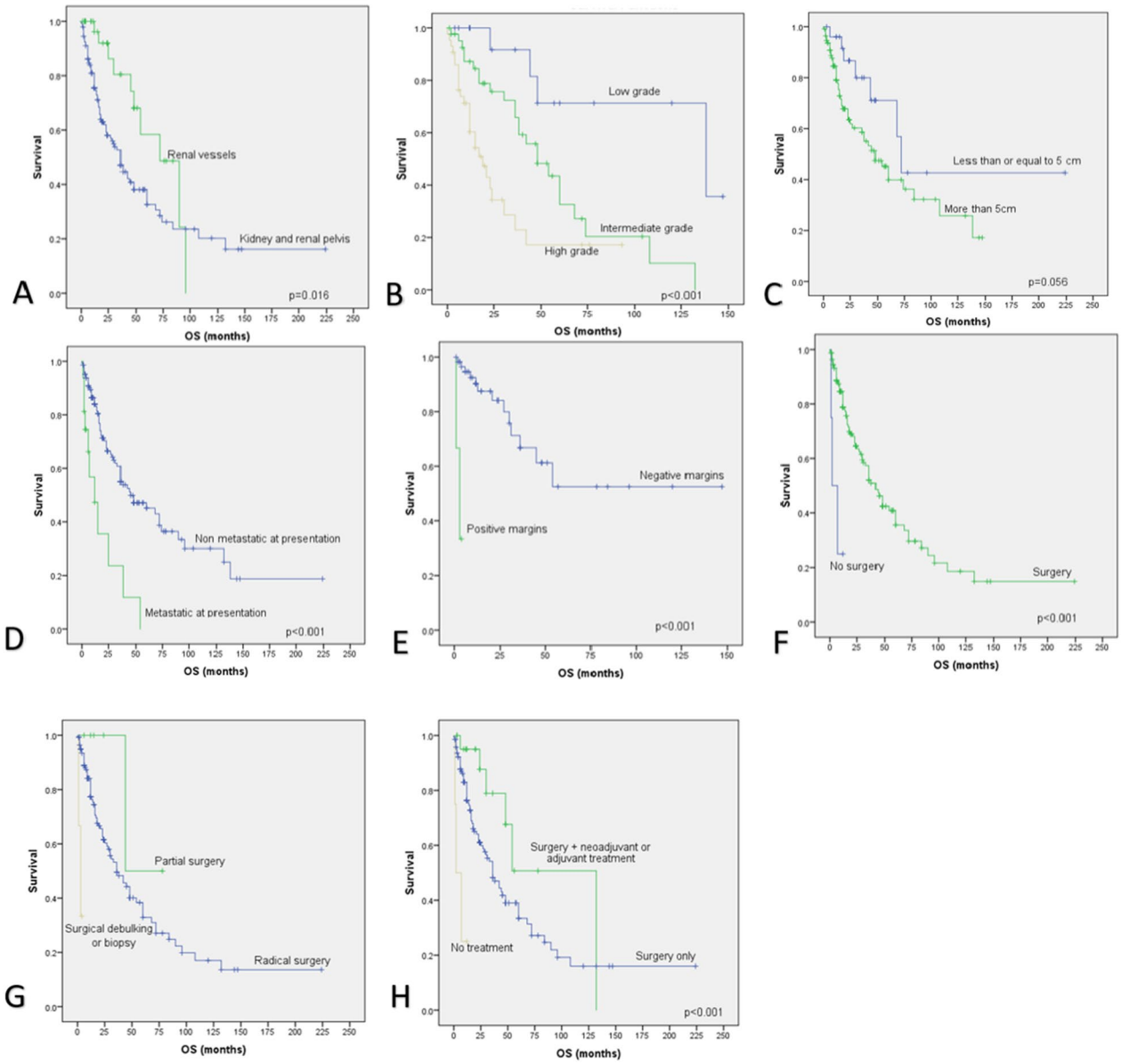

Fig. 3 Kaplan–Meier curves depicting OS according to primary site (**A**), grade (**B**), tumor size (**C**), metastasis at presentation (**D**), resection margins (**E**), surgery vs no surgery (**F**), type of surgery (**G**) and neoadjuvant/adjuvant treatment (**H**)

knowledge, this study is the first analysis reporting survival outcomes of renal LMS as distinct entity.

Primary LMS arising from renal vessels tend to have better prognosis than those from kidney or renal pelvis. Like other sarcomas, the most important prognostic factor was surgical resection status and metastatic disease at presentation [1, 14–16]. We found that patients with no surgical resection and those with positive margins after surgery had worse survival than those with negative margins. Metastatic disease at presentation carried poorer prognosis.

The most critical pathological prognostic feature influencing survival is tumor grade. Deyrup et al. showed that increasing grade of renal LMS and survival is interrelated [5]. High-grade tumors carried poorer survival compared to low and intermediate grade because of their high metastatic potential necessitating adjuvant treatment. Only 8% of patients with intermediate- or high-grade tumors received adjuvant or neoadjuvant treatment in this study. Neoadjuvant therapy was often employed for tumors with risk of positive margins on resection. The 2-year survival of intermediate and high

Table 5 Univariate and multivariate analysis of the factors affecting OS and DFS

Factors	Univariate analysis		Multivariate analysis	
	Hazard ratio (95% confidence interval)	p-value	Hazard ratio (95% confidence interval)	p-value
Overall Survival				
Female gender	0.674 (0.431–1.052)	0.083	0.677 (0.316–1.449)	0.316
Tumour size ≤5cm	0.473 (0.214–1.045)	0.064	0.797 (0.285–2.23)	0.666
Renal vascular origin	0.458 (0.237–0.886)	0.02	0.49 (0.135–1.777)	0.278
Low grade	0.164 (0.05–0.533)	0.003	0.236 (0.067–0.837)	0.025
Non-metastatic disease	0.271 (0.141–0.521)	0.001	0.772 (0.224–2.652)	0.681
Disease free Survival				
Female gender	0.351 (0.164–0.752)	0.007	0.123 (0.012–1.272)	0.079
Tumour size ≤5cm	0.807 (0.395–1.649)	0.556	0.818 (0.079–8.403))	0.866
Renal vascular origin	0.523 (0.153–1.786)	0.301	0.203 (0.024–1.739)	0.146
Low grade	0.012 (0.000–2.694)	0.109	0.005 (0.000–3.412)	0.654
Non-metastatic disease	0.125 (0.039–0.399)	0.001	0.477 (0.026–8.62)	0.616

grade improved by 38% with addition of chemotherapy and/or radiotherapy to surgery (49.4 vs. 80%).

Large tumor size also adversely affected outcomes. The 2-year survival for tumors > 5 cm also improved significantly with combination treatment compared to surgery alone. In a review by Miyajima et al., factors such as age, sex, tumor size, mitotic figures, necrosis and stage affected prognosis [17]. In our analysis, symptomatic patients performed worse as compared to asymptomatic patients. This may be because asymptomatic patients were incidentally diagnosed and hence treated at an early stage. On the other hand, symptomatic patients were most likely diagnosed at advanced stage and thereby had grave prognosis.

Further investigation could benefit from novel insights into its molecular pathogenesis, including genetic mutations or aberrant signaling pathways driving tumor initiation and progression. Exploring the tumor microenvironment's role could elucidate interactions between tumor cells and surrounding stromal components, potentially unveiling novel therapeutic targets or predictive biomarkers. Moreover, in-depth studies characterizing the radiological and histopathological features specific to renal leiomyosarcoma could aid accurate diagnosis and differentiation from other renal neoplasms. Collaborative efforts leveraging multi-omics approaches, such as genomics, transcriptomics and proteomics, could provide a comprehensive understanding of the disease's heterogeneity and inform personalized treatment strategies.

This is the most extensive study of renal LMS reporting on treatment, long-term survival outcomes and prognostic factors, from 188 cases of 85 publications since 1952. Drawing definitive conclusions from this review concerning this uncommon histology is a challenge as there is heterogeneity in data, and completeness of data could not be achieved due to missing information for certain variables in some case reports. However, this study would help to broaden the understanding of natural history of this rare disease.

5 Conclusion

Primary renal LMS is rare entity. Diagnosis is often delayed due to non-specific clinical features and radiological findings. The recommended treatment is radical nephrectomy with en bloc tumor resection with negative margin with adjuvant radiotherapy or chemotherapy specifically for large- and high-grade tumors. Neoadjuvant radiotherapy or chemotherapy may be helpful in unresectable tumors. We wish to highlight the scarcity of available data, which is obvious considering its rarity, not allowing appropriate randomized clinical trials. Hence, we believe that multinational efforts from several centers for sarcomas are required to acquire reliable data from randomized trials regarding best management and validate current treatment strategy.

Acknowledgements

None.

Author contributions

TD helped in data acquisition, analysis and interpretation, manuscript drafting. KP contributed to conception, design, data interpretation, manuscript drafting. SG, RM, RK, CKD, SK and SKD were involved in manuscript drafting and revising. TE and PG helped in data acquisition and manuscript drafting. SGh performed conception, manuscript drafting and revising. All authors have approved the submitted version and agreed both to be personally accountable for the author's own contributions and to ensure that questions related to the accuracy or integrity of any part of the work, even ones in which the author was not personally involved, are appropriately investigated, resolved and the resolution documented in the literature.

Funding
None.

Availability of data and materials
The datasets used and/or analyzed during the current study are available from the corresponding author on reasonable request.

Declarations

Ethics approval and consent to participate
Not required.

Consent for publication
Not applicable.

Competing interests
None.

Author details
[1]Department of Radiotherapy and Oncology, Post Graduate Institute of Medical Education and Research, Chandigarh, India. [2]Department of Urology, Post Graduate Institute of Medical Education and Research, Chandigarh, India. [3]Department of Clinical Oncology, Cambridge University Hospitals, NHS Foundation Trust, Manchester, UK. [4]Department of Radiation Oncology, MPMMCC & Homi Bhabha Cancer Hospital, Varanasi, India. [5]Department of Clinical Haematology and Medical Oncology, Post Graduate Institute of Medical Education and Research, Chandigarh, India.

Received: 24 April 2023 Accepted: 4 March 2024
Published online: 20 March 2024

References

1. Dotan ZA, Tal R, Golijanin D, Snyder ME, Antonescu C, Brennan MF et al (2006) Adult genitourinary sarcoma: the 25-year memorial sloan-kettering experience. J Urol 176(5):2033–2039
2. Mondaini N, Palli D, Saieva C, Nesi G, Franchi A, Ponchietti R et al (2005) Clinical characteristics and overall survival in genitourinary sarcomas treated with curative intent: a multicenter study. Eur Urol 47(4):468–473
3. Beardo P, José Ledo M, Ruiz Campos JL (2013) Renal leiomyosarcoma. Rare Tumors 5(3):144–145
4. Miller JS, Zhou M, Brimo F, Guo CC, Epstein JI (2010) Primary leiomyosarcoma of the kidney: a clinicopathologic study of 27 cases. Am J Surg Pathol 34(2):238–242
5. Deyrup A, Montgomery E, Fischer C (2004) Leiomyosarcoma of the kidney: a clinocapathologic study. Am J Surg Pathol 28(2):178–182
6. Novak M, Perhavec A, Maturen KE, Djokic SP, Jereb S, Erzen D (2017) Leiomyosarcoma of the renal vein: analysis of outcome and prognostic factors in the world case series of 67 patients. Radiol Oncol 51(1):56–64
7. Munn Z, Barker TH, Moola S, Tufanaru C, Stern C, McArthur A, et al. (2019) Methodological quality of case series studies: an introduction to the JBI critical appraisal tool. JBI Database Syst Rev Implement Reports. 2127–33.
8. Health NI of. Study Quality Assessment Tools [Internet]. Available from: https://www.nhlbi.nih.gov/health-topics/study-quality-assessment-tools
9. Hui JYC (2016) Epidemiology and etiology of sarcomas. Surg Clin North Am 96(5):901–914. https://doi.org/10.1016/j.suc.2016.05.005
10. Kendal W (2007) The comparative survival of renal leiomyosarcoma. Can J Urol 14(1):3435–3442
11. Dhawan S, Chopra P, Dhawan S (2012) Primary renal leiomyosarcoma: a diagnostic challenge. Urol Ann 4(1):48–50
12. Choudhury M, Singh S, Pujani M, Pathania O (2009) A case of leiomyosarcoma of kidney clinically and radiologically misdiagnosed as renal cell carcinoma. Indian J Cancer 46(3):241–243
13. Moazzam M, Ather MH, Hussainy AS (2002) Leiomyosarcoma presenting as a spontaneously ruptured renal tumor-case report. BMC Urol 2:13
14. Lee G, Lee SY, Seo S, Jeon S, Ee HL, Choi H et al (2011) Prognostic factors and clinical outcomes of urological soft tissue sarcomas. Korean J Urol 52(10):669–673
15. Lewis JJ, Leung D, Woodruff JM, Brennan MF (1998) Retroperitoneal soft-tissue sarcoma: analysis of 500 patients treated and followed at a single institution. Ann Surg 228(3):355–365
16. van Dalen T, Plooij JM, van Coevorden F, van Geel AN, Hoekstra HJ, Albus-Lutter C et al (2007) Long-term prognosis of primary retroperitoneal soft tissue sarcoma. Eur J Surg Oncol 33(2):234–238
17. Miyajima K, Oda Y, Oshiro Y, Tamiya S, Kinukawa N, Masuda K et al (2002) Clinicopathological prognostic factors in soft tissue leiomyosarcoma: a multivariate analysis. Histopathology 40(4):353–359
18. Aguilar IC, Benavente VA, Pow-Sang MR, Morante CM, Meza L, Destefano V et al (2005) Leiomyosarcoma of the renal vein: case report and review of the literature. Urol Oncol Semin Orig Investig 23(1):22–26
19. Aiken W, Gibson T, Williams S, Gaskin D (2009) Leiomyosarcoma of the kidney. West Indian Med J 58(2):183–184
20. Anoshkin KI, Karandasheva KO, Goryacheva KM, Pyankov DV, Koshkin PA, Pavlova TV et al (2020) Multiple chromoanasynthesis in a rare case of sporadic renal leiomyosarcoma: a case report. Front Oncol 10(August):1–8
21. Appell RA, Thistlethwaite JR (1977) Leiomyosarcoma of renal vein. Urology 9(6):680–681
22. Azizun-Nisa, Hasan SH, Raza Y (2021) Primary renal leiomyosarcoma. J Coll Physicians Surg Pakistan. 21(11): 713–4.
23. Ball ABS, Fisher C (1990) Leiomyosarcoma of the renal vein: a report of two cases. Eur Urol 18(2):150–152
24. Bazaz-Malik G, Gupta DN (1966) Leiomyosarcoma of kidney: report of a case and review of the literature. J Urol 95(6):754–758. https://doi.org/10.1016/S0022-5347(17)63534-1
25. Beccia DJ, Elkort RJ, Krane RJ (1979) Adjuvant chemotherapy in renal leiomyosarcoma. Urology 13(6):652–654
26. Bhathena D, Vazquez M (1972) Primary renal vein leiomyosarcoma. Cancer 30(2):541–544
27. Chatlani PT, Van Dessel MG, McLoughlin GA (1988) Leiomyosarcoma of kidney and breast. Br J Urol 62(4):381–382
28. Cho EY, Yoon JH, Kim W (2013) Leiomyosarcoma of the renal pelvis: report of a case and review of the literature. Omi J Radiol 3:154
29. Chougule A, Bal A, Mandal AK (2015) Primary renal vein leiomyosarcoma: a case report. Cardiovasc Pathol 24(5):332–333. https://doi.org/10.1016/j.carpath.2015.05.002
30. Ciriaco S, García-Espinoza J, Garcia-Pedro E (2018) Primary leiomyosarcoma of kidney with metastasis to contralateral kidney. Case Report Interv Med Appl Sci 10(10):1–4
31. Cocuzza M, Arap S, Lucon AM, Saldanha LB (2005) Renal leiomyosarcoma treated with partial nephrectomy. Clinics 60(4):345–346. https://doi.org/10.1590/S1807-59322005000400013
32. Davis R, Vaccaro JA, Hodges GF, Belville WD, Kiesling V (1992) Renal leiomyosarcoma: Plea for aggressive therapy. Urology 40(2):168–171
33. Demir A, Yazici CM, Eren F, Türkeri L (2007) Case report: good prognosis in leiomyosarcoma of the kidney. Int Urol Nephrol 39(1):7–10
34. Dhamne SA, Gadgil NM, Padmanabhan A (2016), Leiomyosarcoma of the renal pelvis. 4: 8–9.
35. Dominici A, Mondaini N, Nesi G, Travaglini F, Di Cello V, Rizzo M (2000) Cystic leiomyosarcoma of the kidney: an unusual clinical presentation. Urol Int 65(4):229–231
36. Douma S, Kamparoudis A, Petidis K, Anyfanti P, Doumas M, Gkaliagkousi E et al (2012) Leiomyosarcoma of renal vein, initially resembling pheochromocytoma. Clin Exp Hypertens 34(6):429–431
37. Ellouze S, Abid N, Kossentini M, Gouiaa N, Charfi S, Mhiri N et al (2011) Leiomyosarcoma of the kidney. Clin Genitourin Cancer 9(1):68–69. https://doi.org/10.1016/j.clgc.2011.05.001
38. De Sevilla TF, Muñiz R, Palou J, Banús JM, Alegre J, García A et al (1988) Renal leiomyosarcoma in a patient with tuberous sclerosis. Urol Int 43(1):62–64
39. Grasso RF, Giurazza F, Carcione F, D'Agostino F, Del Vescovo R, Faiella E et al (2011) Left renal vein leiomyosarcoma. Gazz Medica Ital Arch per le Sci Mediche 170(4):263–266
40. Gierson ED, Rowe JH (1976) Renal vein leiomyosarcoma. Am Surg 42(8):593–594
41. Gill IS, Hobart MG, Kaouk JH, Abramovich CM, Budd GT, Faiman C (2000) Leiomyosarcoma of the main renal artery treated by laparoscopic radical nephrectomy. Urology 56(4):669
42. Grignon DJ, Ro JY, Papadopoulos NE, Ayala AG (1991) Leiomyosarcoma of renal vein. Urology 38(3):255–258

43. Helmbrecht LJ, Cosgrove MD (1974) Triple therapy for leiomyosarcoma of kidney. J Urol 112(5):581–584
44. Herman C, Morales P (1981) Leiomyosarcoma of renal vein. Urology 18(4):395–398
45. Higbee DR, Atkins DM (1954) Leiomyosarcoma in a double kidney. J Urol 71(2):166–170
46. Imao T, Amano T, Takemae K (2011) Leiomyosarcoma of the renal vein. Int J Clin Oncol 16(1):76–79
47. Inoue K, Watanabe H, Ohashi Y, Morioka M, Fujita Y (1994) Leiomyosarcoma of the renal vein: a case report. J Urol 152(1):153–155
48. Islam MU, Talibi MA, Boyd PF, Laughlin VC (1970) Leiomyosarcoma of kidney. JAMA 212(13):2266–2267
49. Jenkins JD, Anderson CK, Williams RE (1971) Renal sarcoma. Br J Urol 43(3):263–267
50. Kartsanis G, Douros K, Zolota V, Perimenis P (2006) Case report: Leiomyosarcoma of the renal pelvis. Int Urol Nephrol 38(2):211–213
51. Kaufman JJ, Gelbard M (1981) Leiomyosarcoma of renal vein and inferior vena cava. Urology 18(2):173–176
52. Kaushik S, Neifeld JP (2002) Leiomyosarcoma of the renal vein: imaging and surgical reconstruction. Am J Roentgenol 179(1):276–277
53. Krech RH, Loy V, Dieckmann KP, Gerdes J (1989) Stein H Leiomyosarcoma of the kidney Immunohistological and ultrastructural findings with special emphasis on the growth fraction. Br J Urol 63(2):132–134
54. Kretschmer HL (1952) Leiomyosarcoma of the kidney. J Urol 68(1):36–38. https://doi.org/10.1016/S0022-5347(17)68167-9
55. Manoj Kumar G, Nirmal KP (2020) Leiomyosarcoma of renal vein: a case report. Urol Case Rep 31:101186
56. Lazarus JA, Friedmann F (1954) Leiomyosarcoma of the kidney. Am J Surg 87(2):251–258
57. Lea Thomas M, Lamb GH (1978) Angiographic features of a primary leiomyosarcoma of the kidney. Australas Radiol 22(2):155–157
58. Leinwand G, Greenberg J, Sholl A, Krane L (2019) Synchronous Urothelial Bladder and Renal Malignancies. Case report and review of urologic cancers in patients with Familial Rb mutations. Urology 131:89
59. Loertzer H, Krause U, Holzhausen HJ, Hamza A, Fornara P (2004) Development of leiomyosarcoma from primary leiomyoma? Urol Int 73(3):276–279
60. Loomis RC (1972) Primary leiomyosarcoma of the kidney: report of a case and review of the literature. J Urol 107(4):557–560
61. López Varela EA, Pereira GC (1967) Leiomyosarcoma of the renal vein. Case report. Int Surg 47(4):340–343
62. Maeda T, Tateishi U, Fujimoto H, Kanai Y, Sugimura K, Arai Y (2006) Leiomyosarcoma of the renal vein: arterial encasement on contrast-enhanced dynamic computed tomography. Int J Urol Off J Japanese Urol Assoc 13(5):611–612
63. Makis W, Brimo F, Probst S. Primary Renal Leiomyosarcoma Presenting with Subcutaneous and Osseous Metastases: Staging and Follow-Up with 18F-FDG PET/CT. Vol. 52, Nuclear medicine and molecular imaging. Germany; 2018. p. 69–73.
64. Martin J, Garcia M, Duran A, Forcada P, Marco V (1989) Renal vein leiomyosarcoma: a case report and literature review. Urol Radiol 11(1):25–29
65. Minami H, Ueki O, Tanaka T, Nishida H, Hashimoto T, Kawaguchi K (2004) Case of leiomyosarcoma of the renal pelvis. Int J Urol Off J Jpn Urol Assoc 11(2):122–124
66. Montgomery EM, Litvak AS, McRoberts JW (1976) Leiomyosarcoma of renal vein. Urology 8(3):215–217
67. Moudouni SM, En-Nia I, Rioux-Leclerq N, Guille F, Lobel B (2001) Leiomyosarcoma of the renal pelvis. Scand J Urol Nephrol 35(5):425–427
68. Niceta P, Lavengood RWJ, Fernandes M, Tozzo PJ (1974) Leiomyosarcoma of kidney. Rev Lit Urol 3(3):270–277
69. Narula V, Siraj F, Bansal A (2015) Renal leiomyosarcoma with soft tissue metastasis: an unusual presentation. Can Urol Assoc J 9(3–4):E139–E141
70. Ojha S, Nilkanthe R, Valecha J, Meenai F, Haritwal A (2017) Leiomyosarcoma of renal vein–a rare case report. J Clin Diagnostic Res 11(4):3–4
71. Pelton JJ, Palazzo JP, Peterson RO, Eisenberg BL (1990) Renal vein leiomyosarcoma. J Surg Oncol 45(2):131–133
72. Phoa SSKS, Van Rooij WJJ, Kox C, Dijkstra PF (1988) Leiomyosarcoma of the suprarenal and renal veins Report on two cases. RoFo Fortschritte auf dem Gebiete der Rontgenstrahlen und der Nukl. 148(1):84–85
73. Polsky S, Goodloe SJ, Peterson S, Karakousis CP (1997) Leiomyosarcoma of the renal vein. Eur J Surg Oncol 23(5):456
74. Rakowsky E, Barzilay J, Schujman E, Servadio C (1987) Leiomyosarcoma of kidney. Urology 29(1):68–70
75. Radhakrishanan J, Alrenga DP, Ghosh BC. Isolated hepatic metastasis from renal vein leiomyosarcoma. Vol. 102, Archives of pathology & laboratory medicine. United States; 1978. p. 606.
76. Raghavendran M, Kumar A, Gupta R, Srivastava A (2002) Cystic renal leiomyosarcoma: an aggressive tumour. Indian J Urol 18:153–154
77. Roy C, Pfleger D, Tuchmann C, Guth S, Gangi A, Lindner V et al (1998) Small leiomyosarcoma of the renal capsule: CT findings. Eur Radiol 8(2):224–227
78. Selli C, Stefani P, Carcangiu ML, Turini D (1982) Leiomyosarcoma of the kidney: report of two cases with common angiographic findings. Cardiovasc Intervent Radiol 5(5):275–278. https://doi.org/10.1007/BF02565412
79. Sharma D, Pradhan S, Aryya NC, Shukla VK (2007) Leiomyosarcoma of kidney: a case report with long term result after radiotherapy and chemotherapy. Int Urol Nephrol 39(2):397–400
80. Stringer BD (1977) Leiomyosarcoma of artery and vein. Am J Surg 134(1):90–94
81. Tanaka T, Koie T, Iwabuchi I, Ogasawara M, Kawaguchi T, Ohyama C (2014) Primary leiomyosarcoma of a horseshoe kidney in a woman with Turner syndrome: a case report. BMC Res Notes 7:491
82. Tolia BM, Hajdu SI, Whitmore WF (1973) Leiomyosarcoma of the Renal Pelvis. J Urol 109(6):974–976
83. Usawachintachit M, Opanuraks J, Surintrspanont J, Iampenkhae K, Santingamkun A. Leiomyosarcoma of the renal pelvis diagnosed by percutaneous endoscopic resection. Vol. 33, Urology case reports. United States; 2020. p. 101404.
84. van den Berg E, Molenaar WM, van Echten J, Dam A, Mensink HJ, de Jong B (1994) Cytogenetic analysis of a leiomyosarcoma of the kidney. Cancer Genet Cytogenet 72(2):126–129
85. Vos P, Barwegen MGMH, Bakker HHR, Dabhoiwala NF, Schipper MEI (1988) Leiomyosarcoma of the renal vein: a case report. J Urol 139(5):1042–1044. https://doi.org/10.1016/S0022-5347(17)42764-9
86. Yokose T, Fukuda H, Ogiwara A, Sakai K, Saitoh K (1991) Myxoid leiomyosarcoma of the kidney accompanying ipsilateral ureteral transitional cell carcinoma. A case report with cytological, immunohistochemical and ultrastructural study. Acta Pathol Jpn 41(9):694–700
87. Brandes SB, Chelsky MJ, Petersen RO, Greenberg RE (1996) Leiomyosarcoma of the renal vein. J Surg Oncol 63:195–200
88. Cong Z, Lin Z, Wang B, Zhang G, Gong J (2019) Primary renal leiomyosarcoma: CT manifestations and correlation with pathologic findings. Int J Clin Exp Med 12(5):6161–6167
89. Gupta S, Jimenez RE, Folpe AL, Cheville JC (2016) Renal Leiomyoma and Leiomyosarcoma: a study of 57 cases. Am J Surg Pathol 40(11):1557–1563
90. Huang Z, Li H, Ji Z, Shi B (2011) Diagnosis and treatment of primary adult renal sarcoma. Chin Med Sci J 26(3):172–174
91. Maturen KE, Vikram R, Wu AJ, Francis IR (2013) Renal vein leiomyosarcoma: imaging and clinical features of a renal cell carcinoma mimic. Abdom Imaging 38(2):379–387
92. Mucci B, Lewi HJE, Fleming S (1987) The radiology of sarcomas and sarcomatoid carcinomas of the kidney. Clin Radiol 38(3):249–254
93. Ozturk H (2015) High-grade primary renal leiomyosarcoma. Int Braz J Urol 41(2):304–311
94. Srinivas V, Sogani PC, Hajdu SI, Whitmore WFJ (1984) Sarcomas of the kidney. J Urol 132(1):13–16
95. Vogelzang NJ, Fremgen AM, Guinan PD, Chmiel JS, Sylvester JL, Sener SF (1993) Primary renal sarcoma in adults. A natural history and management study by the American Cancer Society, Illinois division. Cancer 71(3):804–810. https://doi.org/10.1002/1097-0142(19930201)71:3%3c804::aid-cncr2820710324%3e3.0.co;2-a
96. Vuruskan BA, Ozsen M, Coskun B, Yalcinkaya U (2019) Evaluation of incidence and histolopathological findings of soft tissue sarcomas in genitourinary tract: uludag university experience. Int Braz J Urol 45(1):68–73

Publisher's Note

Springer Nature remains neutral with regard to jurisdictional claims in published maps and institutional affiliations.