Anand *et al. African Journal of Urology* (2024) 30:14
https://doi.org/10.1186/s12301-024-00416-3

African Journal of Urology

ORIGINAL RESEARCH

Open Access

Feasibility of partial penectomy under local anesthesia: a case–control study

Madhur Anand[1*], Apul Goel[1], Bhupendra Pal Singh[1], Swati Aggarwal[2], Manoj Kumar[1], Vivek Kumar Singh[3] and Vishwajeet Singh[1]

Abstract

Background To assess the feasibility of partial penectomy under local anesthesia and penile nerve blocks.

Methods A total of 45 patients underwent partial penectomy under local anesthesia over the last 15 years at our institute. These patients were included in group A. We took 45 age-matched controls for comparison in group B. All patients underwent partial penectomy with the standard technique. The control group underwent partial penectomy under general or spinal anesthesia, and the intervention group underwent partial penectomy under local anesthesia. Patients' tolerance to anesthesia and surgery was compared, and postoperative pain and other complications were assessed.

Results Mean age was 53.5 years in group A (case) and 52.8 years in group B (controls). Out of 45 patients in group A, 9 were ASA I, 16 were ASA II, 8 were ASA III, and 12 were ASA IV patients. Out of control patients, 35 underwent surgery under spinal and 10 underwent surgery under general anesthesia. All patients tolerated the anesthesia and surgery well. The duration of anesthesia and surgery was shorter in group A ($p < 0.05$). Postoperative pain scores between the two groups were comparable after 6 h. Postoperative recovery was comparable in both groups, and hospital stays were shorter in local anesthesia/nerve block group but were statistically insignificant. There was no positive margin in any group.

Conclusion Partial penectomy under local anesthesia is a satisfactory alternative in selected cases or with limited availability of anesthesia services.

Keywords Penile neoplasms, Penile diseases, Penis cancer, Dorsal nerve of penis

1 Background

Worldwide, India has one of the highest incidences of penile cancer with 0.7–2.3 cases per 100,000 men in urban India, but rates may be as high as 3.32 per 100,000 men in some regions [1, 2]. This is in contrast to the USA and Europe, where the incidence varies from 0.1 to 1.0 per 100,000 population [3]. Most tumors are located on the distal part of the penis and are well to moderately differentiated, hence making penile-sparing techniques feasible for these patients. Partial penectomy is one of the most common surgeries performed and the accepted first-line management for carcinoma penis [4]. However, many of these patients are not in the best of health due to age, untreated comorbidities and poor socioeconomic status and have been linked to adverse outcomes in some cases [5, 6]. There is limited availability of resources and anesthesia and financial constraints.

The utility of regional or local anesthetics is well established for Mohs microscopically controlled surgery and circumcision treatments for carcinoma penis [7, 8]. However, glansectomy and partial penectomy have been traditionally performed under spinal/epidural or general

*Correspondence:
Madhur Anand
drmadhuronline@gmail.com
[1] Urology, King George's Medical University, Lucknow, India
[2] Anaesthesiology, Prasad Institute of Medical Sciences, Lucknow, India
[3] Urology and Renal Transplant, King George's Medical University, Lucknow, India

anesthesia [9]. Local anesthesia as the primary anesthesia technique is heavily underutilized in these patients, even though many more invasive surgeries have been performed under local anesthetics for at least 30 years [10]. The authors communicated with multiple centers before this study and found that many of these centers had some experience with performing partial penectomy under local anesthesia. However, there is a profound lack of published literature concerning this surgery being performed under local anesthesia. In our literature search, we came across *only one published abstract* regarding partial penectomy under local anesthesia [11].

In this retrospective study, we review our experience with performing partial penectomy under local anesthesia or penile nerve block. We also compare the outcomes with retrospective age-matched controls who underwent partial penectomy under spinal, epidural, or general anesthesia, to assess the feasibility and effectiveness of local anesthesia.

2 Methods

This was a retrospective study of prospectively collected data conducted in a tertiary care center. We reviewed our database of the past 15 years to find out the number of partial penectomies. Patients who underwent any other form of surgery apart from partial penectomy (e.g., wide local excision, circumcision, glansectomy, or total/radical penectomy) were excluded. The data were reviewed to find the modality of anesthesia used. Patients who underwent partial penectomy under local anesthesia were included in the case group or group A, and age-matched historical controls were taken from patients who underwent partial penectomy under general anesthesia or spinal/epidural anesthesia in group B.

The standard pathway for all patients with penile cancer at our institute is to clinically evaluate them with detailed history, examination and preoperative investigations. We do a wedge biopsy from the edge of growth and contrast-enhanced computed tomography for inguinal lymph nodes at the first visit itself. On the second outpatient visit, the biopsy reports and preoperative workup are reviewed, and a pre-anesthetic checkup is done for the planned surgery. Then the patients are admitted the evening before the surgery for surgery the next morning. All surgeries were conducted in the presence of an anesthesiologist for conversion to general anesthesia in the event of any failure of the penile nerve block or local anesthesia. All patients were followed up 24 h later for pain scores and any complications.

Demographic details, preoperative biopsy findings, American Society of Anaesthesiologists classes and operative risk as per pre-anesthetic checkups were retrieved. Operative records were reviewed to document the operating time, blood loss (as per the number of 10 ml gauze soaked), intraoperative events, analgesics and anesthesia top-ups and the patient's tolerance of the procedure and any intraoperative pain. Pain scores were reported by the patients on a numeric scale on 0 to 10 with 0 being no pain and 10 being the worst possible pain. Postoperative pain scores, duration of hospital stay, any complications postoperatively, and histopathology outcomes were also reviewed and analyzed. Statistical Analysis of the characteristics of the two groups was done by IBM-SPSS version 29. Apart from the descriptive statistics, the means of the independent samples were compared by the t test. The study was approved by the Institutional Ethics Committee.

2.1 Relevant anatomy and technique

The penis is innervated from sacral nerve roots S2 to S4 via the pudendal nerve, accompanied by branches of the internal pudendal artery in the pudendal canal. It innervates the penis after dividing into dorsal penile and perineal branches. The dorsal penile nerve passes deep to the suspensory ligament and under the inferior ramus of the pubis to continue directly within Buck's fascia, next to the dorsal vessels. The frenulum also receives supply from perineal nerve branches (Fig. 1).

For the penile nerve block, we follow the technique described by Szmuck et al., where we inject 10 ml of plain lignocaine 0.5–1% solution deep to the Buck's fascia [12]. As highlighted by Long et al., we prefer performing

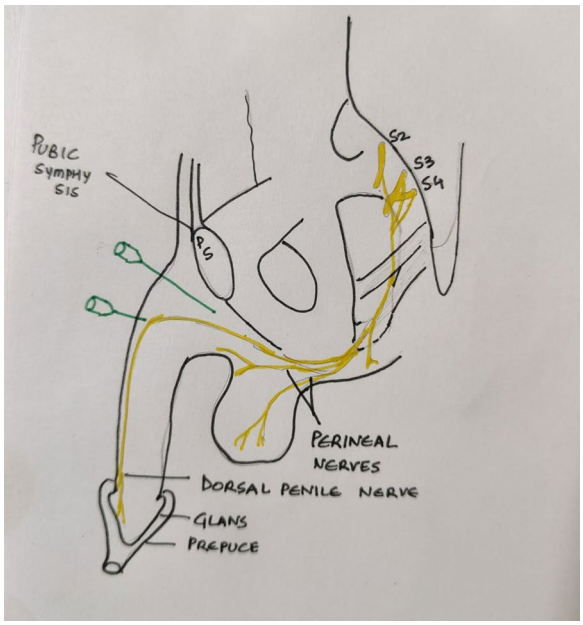

Fig. 1 Schematic diagram of sensory nerve supply of penis for penile nerve block

this block along with infiltration of the ventral surface to block the sensation carried by perineal nerves [13]. To confirm the plane of the needle while performing the block, we use ultrasound guidance. The ultrasound image of the block is shown in Fig. 2.

We use the ring block technique for local anesthesia infiltration, in case an ultrasound-guided approach is not available due to logistic reasons. For this, we utilize the technique described by Szmuck et al. in group C of their study and infiltrate approx. 10 ml of plain lignocaine in 0.5–1% concentration [12]. All patients operated under local anesthesia or nerve block were operated in the presence of an anesthetist standby, and intraoperative pulse, noninvasive mean arterial pressure and peripheral oxygen saturation monitoring were done. Intravenous (IV) access was secured; however, no IV fluid or analgesic drips were given as a routine. All patients at the end of surgery underwent reinjection of 10 ml of plain lignocaine in 0.5–1% concentration for postoperative pain control. The patients were managed on injectable analgesics (paracetamol 1 g infusion three to four times daily IV, Diclofenac or tramadol as needed) with a buprenorphine patch for the first 24 h and then shifted to oral analgesics (tramadol 37.5 mg + paracetamol 325 mg or diclofenac) three to four times a day along with preexisting buprenorphine patch.

We perform penile-sparing surgeries for carcinoma penis with tourniquet to minimize blood loss and utilize the parachute technique described by Korkes et al. for ventral spatulation and neomeatus construction [14]. We do not routinely send intraoperative frozen sections during partial penectomy. For histological grade 1–2 lesions, we prefer a gross margin of at least one cm with a residual stump length of at least 2 cm to consider a partial penectomy. In high grade, locally recurrent, or in patients with residual disease (referred from other centers after circumcision), we prefer taking at least a 2 cm margin. We consider partial penectomy in these cases only if the residual stump length fulfills the criteria of 2 cm for partial penectomy, after a 2 cm margin. We do our lymph node dissections as indicated by the post-resection histopathology of penile growth. This allows the penile stump to heal. However, we prefer to perform it within 6 weeks

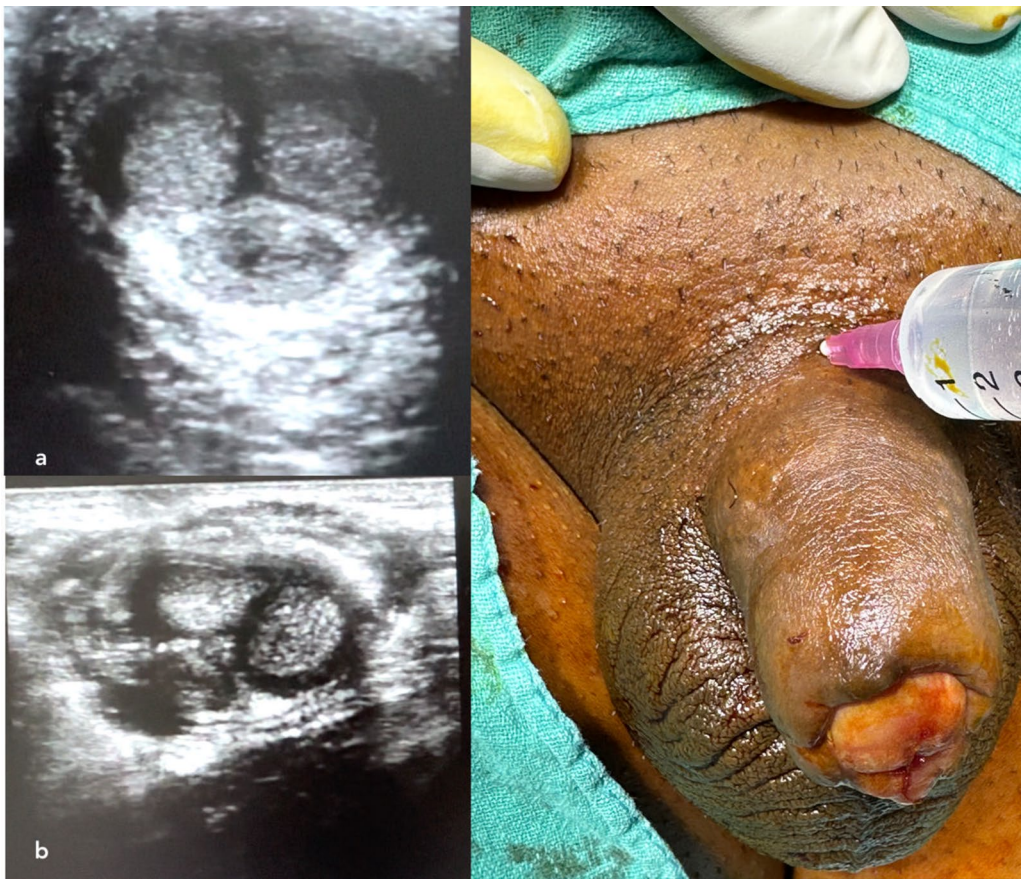

Fig. 2 Ultrasound-guided penile nerve block. **a** Subcutaneous infiltration, **b** infiltration deep to Buck's fascia, c position of needle during block administration

of penectomy [15]. For this study, the data regarding lymph node dissection were not analyzed.

3 Results

A total of 45 patients underwent partial penectomy under local anesthesia over the last 15 years at our institute. The mean age of the patients was 53.49 ± 7.33 years. The ASA classifications and type of anesthetic technique are described in Table 1. Group A had more patients with ASA class III and IV compared to the control group. The intraoperative and postoperative pain scores were higher in the group A compared to controls, with statistically significant p-values. However, the overall duration of the utilization of the operating room, i.e., the time taken to administer the anesthesia and perform the surgery, was shorter in the local anesthesia/nerve block group and this difference was statistically significant (Table 1).

Table 2 summarizes the intraoperative analgesic requirements and postoperative analgesic regimen used for the patients which was comparable in both groups. Postoperative analgesic requirements were comparable for the two groups. While some patients required local anesthetic top-up in group A and one patient in group B required sedation due to apprehension, none required conversion of the anesthesia technique in both groups. The blood loss (Table 1) and hospital stay (Table 2) were higher in the control group, but the difference did not reach statistical significance. All patients had complete resection of tumors with negative surgical margins and no significant postoperative complications after surgery. Five patients across the two groups required removal of sutures of the penile stump due to wound infection; however, this was done on an outpatient basis, and no other reintervention was required. Therefore, they were classified as having Clavien-Dindo grade 1 complications. The remaining patients were classified as having Clavien-Dindo grade 1 for the pain. Group B had more patients with the pT3 stage; however, the other pathological stages were somewhat similar in both groups. Overall, group A had relatively smaller growths compared to the control group. On subgroup analysis, the outcomes of both local anesthesia and nerve block were comparable (Table 3).

4 Discussion

Limited penile resections are the standard of care in suitable patients for the management of primary lesions in carcinoma penis [15]. Various authors have performed multiple types of penile surgeries under local anesthesia or nerve block. The commonly performed procedures are circumcision, visual internal urethrotomy and wide local excision for penile growths [16–18]. However, some authors have even reported doing penile implants and surgery for Peyronie's disease under local anesthesia [10, 11].

The literature on partial penectomy under local anesthesia is scant, mainly because it is a disease of developing countries, and during our literature search we did not come across any comparative study about the same. In our extensive literature search, apart from a published abstract of a case series on partial penectomy under local anesthesia, no other literature was available. In this study, the authors demonstrated acceptable outcomes with 27/28

Table 1 Patient characteristics and pain scores of the two groups

Characteristic	Group A (local/penile nerve block) N = 45	Group B (spinal/epidural or general anesthesia) N = 45	P-value (< 0.05: significant)
Age in years (mean ± 2SD)	53.49 ± 7.33	52.71 ± 6.23	0.516
ASA I	9	11	0.275
II	16	18	
III	8	9	
IV	12	7	
Anesthesia Modality	Penile nerve block 12	Spinal/epidural anesthesia: 35	
	Local anesthesia 33	General anesthesia: 10	
Intraoperative pain score (mean)	0.47	0.04	0.002
Mean pain score at 1 h (mean)	1.86	0.56	< 0.001
Mean pain score at 6 h (mean)	2.33	2.27	0.807
Mean pain score at 24 h (mean)	1.8	1.84	0.850
Duration of anesthesia + surgery (mean) minutes	43.13	48.98	< 0.001
Blood loss (Mean)	26	27.78	0.356
Mean lesion size (SD)	3.02 cm (1.59)	4.71 cm (1.34)	< 0.001

Table 2 Analgesic requirements, stage, complications, margin status and hospital stays of the two groups

Characteristic	Group A (local/penile nerve Block) N = 45	Group B (spinal/epidural or general anesthesia) N = 45	P-value (< 0.05: significant)
Additional analgesia required during the surgery			
Local anesthesia top-up	6	1	0.025
Conversion to general anesthesia	0	0	
Sedation	0	1	
Epidural top-up	0	2	
Intravenous analgesia Paracetamol	2	2	0.078
Postoperative analgesics			

	Group A (Case)		Group B (Control)		P-value
	Number of patients (Case) (n = 45)	Mean Number of doses (Case)	Number of patients (Control)	Mean Number of doses (Control)	
Paracetamol 10 mg/kg TID/QID	45	3.4	45	3.3	0.223
Diclofenac SOS	10	1.3	7	1.1	0.314
Tramadol SOS	3	1	3	1.3	0.367
Buprenorphine patch	2	1	3	1	0.325
pT Stage (AJCC 8th ed) pT1a pT1b pT2 pT3	7 14 16 12		6 11 13 15		
Mean postoperative hospital stay (hours)	21.68 h		22.6 h		0.628
Mean Clavien-Dindo score Description (if any)	1 (mainly pain) Two patients required removal of penile stump stitches on OPD basis, Clavien-Dindo score 1)		1 Three patients required removal of sutures on OPD basis		
Positive margins	0		0		

Table 3 Comparison of local anesthesia and penile nerve block for partial penectomy

Variable	LA	NB	*p*-value (one-sided/ two-sided)
Number	33	12	
Lesion size	2.85 (SD 1.64)	3.50 (SD 1.38)	0.114/0.228
Intraop pain	0.33 (SD0.645)	0.83 (SD 1.337)	0.049/0.098
Intraop lignocaine	0.09 (0.292)	0.25 (0.452)	0.086/0.173
Intraop PCM	0.0	0.17 (0.389)	0.008/0.16
Intraop Fentanyl	0.0	0.17 (0.389)	0.008/0.16
Postop pain 1 h	1.67 (0.890)	2.42 (1.621)	0.027/0.054
Postop pain 6 h	2.67 (1.497)	2.21 (1.386)	0.173/0.346
Postop pain 24 h	1.76 (1.226)	1.92 (0.793)	0.339/0.678
Postop PCM	3.39	3.50	0.284/0.568
Postop Diclo	0.24	0.42	0.193/0.386
Postop tramadol	0.06	0.08	0.396/0.793
Bupre patch	0.03	0.08	0.228/0.457
Hospital stay	22.39 (10.09)	19.75 (6.784)	0.203/0.407

patients being operated on successfully under local anesthesia [11]. Only limited data were available in this abstract about the study design and methodology. This study from the UK was done over 8 years in 9 partial penectomies, 17 glansectomies and one open distal urethrectomy, and they reported the block to be successful in 96% of cases. Our series, therefore, is the largest series of only partial penectomies, performed under local anesthesia and penile nerve blocks.

We started performing partial penectomies under local anesthesia for high-risk patients and small growths. However, we have gradually extended this technique to relatively fit patients too. We feel that the patients need to be carefully counseled for local anesthesia and should not be apprehensive about the procedure or intraoperative pain. The awareness of touch and pressure sensations [19] makes the patients apprehensive about the procedure in our experience. Therefore, we always keep an anesthesiologist on standby to address any such intraoperative event. Our

experience shows that for relatively smaller growths, local anesthesia or nerve block is effective alternative. While our data shows that the difference between the pain scores of groups A and B is statistically significant, the clinical significance of this difference is doubtful. To achieve an equivalent result to spinal or general anesthesia in terms of postoperative pain control, additional infiltration with lignocaine toward the end of the procedure helps in postoperative pain control in our experience. We did not use bupivacaine in our current series, as we have limited experience with it. However, with experience, this agent may be added to prolong postoperative analgesia. For margins, we rely on induration and initial biopsy findings and counsel the patient for partial penectomy only if, after adequate margin, the residual stump is more than 2 cm. All penectomies in our center are done on a tourniquet to minimize bleeding [20].

In patients operated under spinal anesthesia, one patient experienced pain and therefore required to be sedated after he was unrelieved with additional local anesthesia and intravenous paracetamol; two patients were administered epidural top-up for postoperative pain control. One patient operated under spinal anesthesia was administered intravenous paracetamol toward the end of the procedure for postoperative analgesia.

Among patients operated under local anesthesia or nerve block, two cases required supplementation with intravenous analgesia. Out of these two, one patient required paracetamol 1000 mg and diclofenac 75 mg, while the other was relieved after fentanyl 1 µg per KG. The choice of intravenous analgesia was at the discretion of the anesthesiologist.

In our setup, partial penectomy is a daycare procedure. Especially after surgery under local anesthesia, we have discharged well-tolerating patients in less than 24 h postoperatively too, provided patients fulfill the requirements for daycare surgery like adequate access, responsible caregivers at home and social support for any eventuality [21].

The present study highlights the feasibility and effectiveness of partial penectomy under local anesthesia and penile nerve block for the management of squamous cell carcinoma of the penis. The study's results indicate that this technique can be a suitable alternative to the traditional method of general anesthesia, particularly for those with underlying conditions that may predispose them to complications under general anesthesia. However, the limitations of this approach include inability to perform inguinal node biopsy/lymph node dissection in same anesthesia, slightly higher postoperative pain scores and patient apprehension in some cases.

There are certain limitations to our study, namely the retrospective study design and selection bias, as evident with higher ASA scores of group A and higher pT3 stage of group B. There was no predefined anesthesia or analgesia protocol used in our patients. Relatively smaller growths were assigned to local anesthesia group which clearly reflects a selection bias. Also for the sample size available to us, the study is underpowered. An appropriately powered comparative prospective study or randomized trial will be able to give better recommendations regarding factors associated with the success of this approach and selection criteria for the enrollment of patients.

5 Conclusion

In conclusion, partial penectomy under local anesthesia and penile nerve block is a viable option for the management of squamous cell carcinoma of the penis, especially in patients with significant comorbidities or when the anesthesia facility is at a premium. In carefully selected patients, it can be as good as general or spinal anesthesia; however, the oncological safety should not be compromised when planning a case under local anesthesia or penile nerve block.

Abbreviations

ASA	American Society of Anaesthesiologists
IBM	International Business Machines
SPSS	Statistical Package for the Social Sciences
UK	United Kingdom

Acknowledgements

Department of Anaesthesiology and Pathology, King George's Medical University, Lucknow, for their support in patient management.

Author contributions

MA and SA performed data collection, analysis and writing first draft. BPS and AG performed overall clinical supervision and reviewing of the first draft. MK, VKS and VS performed critical revision.

Funding

This study received no funding in any forms.

Availability of data and materials

The datasets used and/or analyzed during the current study are available from the corresponding author on reasonable request.

Declarations

Ethics approval and consent to participate

Ethical approval was obtained for conducting this study from the Institutional Ethics Committee of King George's Medical University, Lucknow (Ref. Code: 129th ECM IIA/P4, 30/11/2023). Informed written consent to participate in the study was provided by all participants. Institutional ethics committee approval was obtained for conducting this study.

Consent for publication

Consent for publication of deidentified data was obtained from all participants.

Competing interests

The authors declare that they have no competing interests.

Received: 2 January 2024 Accepted: 17 February 2024
Published online: 12 March 2024

References

1. Latha DPS, Chaitanya DB, Reddy DSR (2014) A Pathologist's perspective of penile carcinoma—an Institutional study at Indian Red Cross Hospital, Nellore. Int J Med Res Rev 2(1):21–25. https://doi.org/10.17511/ijmrr.2014.i01.05
2. Montes Cardona CE, García-Perdomo HA (2017) Incidence of penile cancer worldwide: systematic review and meta-analysis. Rev Panam Salud Publica 41:e117. https://doi.org/10.26633/RPSP.2017.117
3. Vieira CB, Feitoza L, Pinho J, Teixeira-Júnior A, Lages J, Calixto J et al (2020) Profile of patients with penile cancer in the region with the highest worldwide incidence. Sci Rep 10(1):2965. https://doi.org/10.1038/s41598-020-59831-5,PMID32076037
4. Sakalis VI, Campi R, Barreto L, Perdomo HG, Greco I, Zapala Ł et al (2022) What is the most effective management of the primary tumor in men with invasive penile cancer: a systematic review of the available treatment options and their outcomes. Eur Urol Open Sci 40:58–94. https://doi.org/10.1016/j.euros.2022.04.002,PMID35540709
5. Garcia L, Reis LO, García-Perdomo HA (2021) Living in a rural area as a risk factor for worst outcomes in penile cancer. Int Braz J Urol 47(6):1259–1263. https://doi.org/10.1590/S1677-5538.IBJU.2021.99.15
6. Akinyemi OA, Fasokun ME, Weldeslase TA, Adeoye O, Coleman PW. Influence of race/ethnicity and household median income on penile cancer mortality. Cureus. June 24, 2023;15(6):e40909. doi: https://doi.org/10.7759/cureus.40909, PMID 37496530.
7. Dirr MA, Christensen RE, Anvery N, Nadir U, Schaeffer M, Veledar E et al (2023) Pain of local anesthetic injection of lidocaine during subsequent stages of Mohs micrographic surgery: a multicenter prospective cohort study. J Am Acad Dermatol 89(1):114–118. https://doi.org/10.1016/j.jaad.2023.02.049,PMID36907555
8. Lenhart JG, Lenhart NM, Reid A, Chong BK (1997) Local anesthesia for circumcision: which technique is most effective? J Am Board Fam Pract 10(1):13–19
9. Ranjan SK, Ghorai RP, Kumar S, Usha P, Panwar VK, Kundal A (2021) Modified "parachute technique" of partial penectomy: a penile preservation surgery for carcinoma penis. J Fam Med Prim Care 10(2):1054–1056. https://doi.org/10.4103/jfmpc.jfmpc_1784_20,PMID34041123
10. Hsu GL, Long, Hsieh, Hsing, Chen, Shuen, Ling, Ying, and Ceferino Chua. "The Advancement of Pure Local Anesthesia for Penile Surgeries: Can an Outpatient Basis Be Sustainable?" *Journal of Andrology 28*. 2007;1:200–5. doi: https://doi.org/10.2164/jandrol.106.000679.
11. Winyard JC, Berridge C, Goddard JC, Summerton JC (2021) Local anaesthetic surgery for penile cancer—An under-utilised option? Br J Surg 108(Suppl):2. https://doi.org/10.1093/bjs/znab134.265
12. Szmuk P, Ezri T, Ben Hur H, Caspi B, Priscu L, Priscu V et al (1994) Regional anaesthesia for circumcision in adults: a comparative study. Can J Anesth 41(12):1181–1184. https://doi.org/10.1007/BF03020658
13. Long RM, McCartan D, Cullen I, Harmon D, Flood HD (2010) A preliminary study of the sensory distribution of the penile dorsal and ventral nerves: implications for effective penile block for circumcision. BJU Int 105(11):1576–1578. https://doi.org/10.1111/j.1464-410X.2009.09044.x,PMID19889061
14. Korkes F, Neves-Neto OC, Wroclawski ML, Tobias-Machado M, Pompeo AC, Wroclawski ER (2010) Parachute technique for partial penectomy. Int Braz J Urol 36(2):198–201. https://doi.org/10.1590/s1677-55382010000200010
15. Kamel MH, Bissada N, Warford R, Farias J, Davis RS (2017) Organ sparing surgery for penile cancer: a systematic review. J Urol 198(4):770–779. https://doi.org/10.1016/j.juro.2017.01.088
16. Biswal DK, Ghosh B, Bera MK, Pal DK (2016) A randomized clinical trial comparing intracorpus spongiosum block versus intraurethral lignocaine in visual internal urethrotomy for short segment anterior urethral strictures. Urol Ann 8(3):317–324. https://doi.org/10.4103/0974-7796.184901
17. Ye G, Shan-Hong Y, Xiang-Wei W, Hua-Qi Y, Rong-Gui Z (2005) Use of new local anaesthesia—intracorpus spongiosum anaesthesia—in procedures on the anterior urethra. Int J Urol 12(4):365–368. https://doi.org/10.1111/j.1442-2042.2005.01057.x,PMID15948723
18. Ye G, Rong-gui Z (2002) Optical urethrotomy for anterior urethral stricture under new local anaesthesia: intracorpus spongiosum anaesthesia. Urology 60(2):245–247. https://doi.org/10.1016/s0090-4295(02)01732-6,PMID12137820
19. de Abreu CCL (2018) Local Anesthesia. Dermatologic surgery and procedures. INTECH. https://doi.org/10.5772/intechopen.72930
20. Parsons BA, Kalejaiye O, Mohammed M, Persad RA (2013) The penile tourniquet. Asian J Androl 15(3):364–367. https://doi.org/10.1038/aja.2012.164
21. Bailey CR, Ahuja M, Bartholomew K, Bew S, Forbes L, Lipp A et al (2019) Guidelines for day-case surgery 2019. Anaesthesia 74(6):778–792. https://doi.org/10.1111/anae.14639

Publisher's Note