African Journal of Urology

ORIGINAL RESEARCH

Open Access

Nephron sparing surgery for renal hilar tumours: short-term follow-up of predominantly robot-assisted surgery cohort

Anandan Murugesan[1*], Ramesh Chinnusamy[1] and Devdas Madhavan[1]

Abstract

Background Hilar tumours are the renal tumours, which abut the renal artery or vein. Nephron sparing surgery (NSS) is of proven benefit among those with small renal masses. Hilar tumours are usually offered radical surgery due to the presumed difficulty in dissection, upgrading to tumour stage, and risk of conversion to radical surgery. We present our results of patients with hilar tumour undergoing nephron sparing surgery.

Methods We performed a retrospective analysis of patients who underwent NSS for renal hilar tumours in our tertiary referral institute from June 2017 to December 2022. The case sheets of all the patients who had undergone NSS were analysed and their radiology images reviewed. Those with hilar tumours were analysed based on demographic characters, perioperative and postoperative and follow-up details.

Results Among a total of 21 patients undergoing partial nephrectomy, ten had hilar tumours. The median age was 43 years. Nine patients had robot-assisted partial nephrectomy and one underwent open partial nephrectomy. Seven patients had incidentally detected tumours. One had Grade 3 chronic kidney disease. The mean operative time and robot console time were 225 and 125 min, respectively. Median warm ischaemia time (WIT) was 36 min (25–48 min). One patient had grade 2 complication and two had grade 3 complication. Eight had clear cell renal cell carcinoma and one had positive margin. None had recurrence at a median follow-up of 38 months.

Conclusion Nephron sparing surgery, especially with robot-assisted approach, is feasible in hilar tumours with prognosis and complications similar to non-hilar tumours in short-term follow-up.

Keywords Renal tumour, Hilar tumour, Nephron sparing surgery, Robotic partial nephrectomy, Follow-up

1 Background

Nephron sparing surgery (NSS) is the treatment of choice for clinically T1a and some T1b and T2 tumours[1]. Renal hilar tumours are those tumours which abut the renal artery or vein in the renal hilum [2, 3]. Though nephrometry scoring is used to assess the complexity of renal tumours, hilar tumours form a special group due to their proximity to major renal vessels [4].

Radical surgery was usually offered in many centres for hilar tumours [5]. NSS in such tumours is surgically challenging and mainly performed in high volume centres. The probable reason for less use of NSS in these tumours is the probability of upstaging to T3a (sinus involvement), though studies suggest otherwise [6]. The other reason could be the need for precise dissection near the hilum. Robot-assisted surgery has increased the feasibility of such surgery with the better dexterity and magnification [7]. Robotic surgery has expanded the indication for NSS

*Correspondence:
Anandan Murugesan
anandan79@gmail.com
[1] Department of Urology, Kovai Medical Center and Hospital, Post Box No 3209. Avinashi Road, Coimbatore, Tamilnadu 641014, India

to even include synchronous ureteric and renal tumours [8].

NSS should be offered to these small tumours since the benefits are manifold. Many patients present in the fourth or fifth decade with incidentally detected tumours [9]. Comorbidities like diabetes and hypertension, which might compromise renal function are prevalent in elderly age group. Radical nephrectomy in these patients make them more prone to chronic kidney disease (CKD) [10]. Patient acceptance and quality of life is also better among those offered NSS [11, 12]. Hence NSS should be offered even to those with hilar small renal tumours. We present the results of short-term follow-up of patients undergoing NSS for hilar tumours.

2 Methods

We conducted a retrospective analysis of the patients who underwent partial nephrectomy for renal hilar tumours in our quarternary care institute from June 2017 to December 2022. Institutional ethical committee clearance was obtained and the case records of the patients who underwent partial nephrectomy were retrieved. Contrast enhanced Computed Tomography (CECT) images of the patients were analysed and those tumours which were abutting the renal artery and/or renal vein were classified as hilar tumours. The preoperative clinical parameters, preoperative details and postoperative course and minimum of 1 year follow-up details were analysed. All the surgeries were done by a single surgeon.

2.1 Surgical technique

Under General anaesthesia, all the patients had retrograde ipsilateral ureteric catheterization and urethral catheter insertion.

2.2 Open partial nephrectomy

In lateral kidney position, 11th rib bed approach was used for exposure of the kidney. Uretero gonadal packet was dissected and traced till hilum and the renal artery and vein was dissected and looped. Gerota's fascia was opened and perirenal fat excised leaving some fat around the tumour. Artery was clamped and tumour divided with a rim of renal tissue margin. Three layer renorrhaphy was done, clamp released and haemostasis ensured. Nephropexy was done, and drain was placed.

2.3 Robot-assisted partial nephrectomy

Patient was placed in lateral kidney position, and standard 6 ports were placed. Colon was deflected medially and uretero gonadal packet was dissected and traced till hilum. Renal artery and vein were dissected and looped separately. For the tumours located in the interpolar region over the hilum, intrasinus dissection of the renal vessels was done along the Gilvernet plane, till the tumour was elevated from the vessels. The branches and tributaries infiltrating or supplying the tumour were clipped and cut. Tumour elevation was done as much laterally as possible. Kidney was mobilised all around. Perirenal fat was excised from the kidney leaving some part intact around the tumour. Tumour margin was marked cognitively based on the CT images in partially endophytic tumours. Renal artery alone was clamped and tumour was divided with a rim of normal renal tissue and three layer renorrhaphy was done. Declamping was done, haemostasis ensured, specimen retrieved and drain placed.

Our technique of three layer renorrhaphy in hilar interpolar tumours is fairly standardised. The first layer of 4-0 Polydioxanone suture is used to close the pelvicalyceal system and open blood vessels in the sinus fat. The second layer consists of 3-0 barbed sutures close the part of the renal sinus fat and inner parenchymal layer. Barbed sutures help to avoid constant traction and possibility of suture cut through. The closure is along supero inferior axis (bringing upper and lower pole closer). Finally, mass closure is done with 1-0 poly glactin suture by sliding clip technique along the same plane (Additional File 1: Fig. S1, Additional File 2: Fig. S2, Additional File 3: Fig. S3).

Postoperatively, orals feeds were started on day 1, ureteric and urethral catheter removed on day 3 and drain removed on day 3 or 4 and discharged after doppler study of kidney. Follow-up with biochemical analysis (Serum Creatinine and estimated Glomerular filtration rate (eGFR) by Modification of Diet in Renal Disease (MDRD) equation) at 3 months and CECT and biochemical analysis at 1 year.

2.4 Statistical analysis

Quantitative data were expressed as mean, standard deviation, median and range as appropriate. Qualitative data were expressed as frequency and percentage. The percentage change in Se.Creatinine (eGFR) between preoperative values and postoperative values were analysed.

3 Results

A total of 21 patients underwent partial nephrectomy, one open and 20 robot-assisted procedures. Out of them ten patients had hilar tumours. Their details were analysed.

The basic demographic and preoperative details are summarised in Table 1. The median age of the patient was 43 yrs (23–63 yrs). Six of the patients were men. Presenting symptoms were varied. One of them had microscopic hematuria, two patients had non-specific loin pain and found to have renal mass on evaluation. The rest of them (seven) were detected during routine screening during

Table 1 Patient characteristics

Total partial nephrectomy	21
Hilar tumours	10
Age	43 yrs (23–63 yrs)
Male: Female	3:2
Presentation	Incidental detection-7 Loin pain-2 Hematuria-1
Comorbidities	3 (Diabetes-1, Hypertension & Hypothyroidism–1, Chronic kidney disease stage 3–1)
Radiological investigation	CECT-9, MRI-1
Tumour size	6.2 cm (3.8–9.2 cm)
Tumour location	Upper pole-3, Interpole-6, Lower pole-1
Surgery approach	Open-1; Robot-assisted-9
Total operative time	(Mean) 225 min (10 cases)
Console time	(Mean) 125 min (9 cases)
Warm ischaemia time	(median) 36 min
Estimated blood loss	(Mean) 170 ml
Median follow-up	38 mths (12–71 mths)
Complications	Grade III–2 Grade II–1
Histopathology	Clear cell carcinoma-8 (T1a-1; T1b-6, T2a-1) Grade 3–1; Grade 2–4, Grade 1–3 Papillary carcinoma-1 Oncocytoma-1
Positive margin	1

health check up. None of them had any significant clinical findings. Two patients had diabetes and hypertension and one of them was also hypothyroid. One patient had CKD stage 3 and was on conservative management. Biochemical and clinical pathology parameters were unremarkable, except in the patient with CKD.

Three patients had predominantly upper polar tumour, one had lower polar tumour and six had interpolar tumour on cross-sectional imaging (Figs. .1, 2). The patient with CKD had Magnetic resonance imaging and the rest had CECT for radiological evaluation. One of the upper polar tumour patient had double ureter. Chest radiograph was unremarkable.

The patient with double ureter underwent open procedure due to patient preference and the other eight underwent robot-assisted partial nephrectomy with no open conversion. The mean operative time and robot console time were 225 and 125 min, respectively. Median warm ischaemia time (WIT) was 36 min (25–48 min). The mean estimated blood loss was 170 ml.

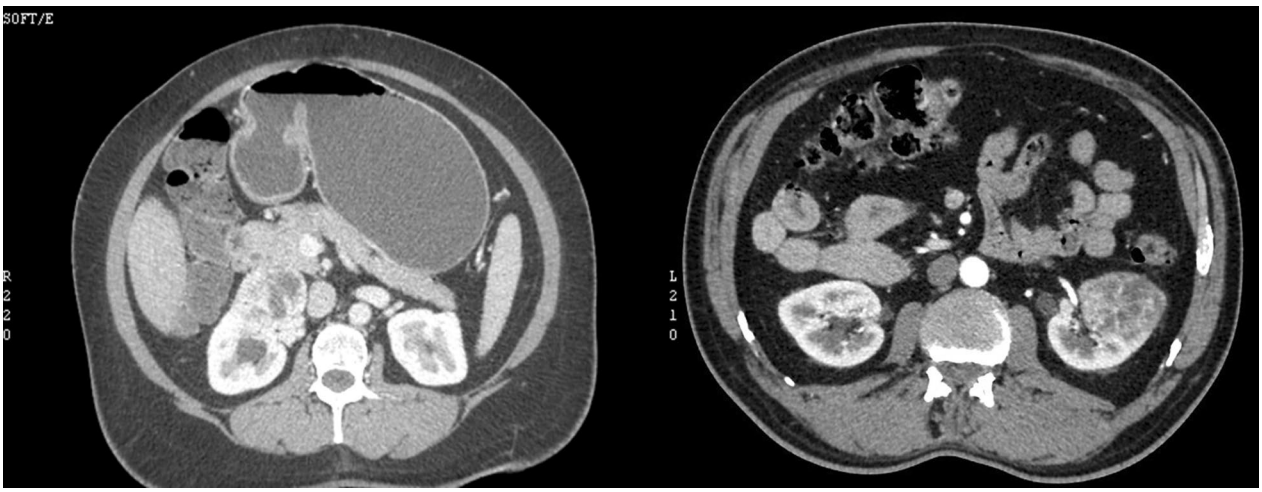

Fig. 1 CECT axial section showing interpolar hilar tumour

Fig. 2 CECT sagittal image showing hilar tumour

One patient had intraoperative renal vein tributary injury which was managed with primary suturing (Fig. 3). Four had arterial branch supplying the tumour, which was clipped and cut superselectively during intra sinus dissection (Fig. 4). One patient received blood transfusion. One patient had pseudoaneurysm on follow-up doppler and underwent angioembolisation (Fig. 5). The patient with double ureter developed urinoma at 1 month follow-up which was managed with stenting and aspiration. On Clavien Dindo classification, one had grade 2 complication and two had grade 3.

Histopathology examination showed eight with clear cell renal cell carcinoma (one T2a, six T1b and one T1a), one had papillary renal cell carcinoma (T1b) and one patient had oncocytoma. One clear cell tumour had 1 mm positive margin, rest had negative margins. The median follow-up was 38 months. The patient with positive margin had no recurrence at 3 years follow-up.

The mean change in Se. Creatinine and eGFR between preoperative and postoperative values was 10%. The masterchart is provided as Additional File 4 (Table 1).

4 Discussion

NSS is the treatment option for small renal masses irrespective of location. Relatively more widespread availability of robotic surgeries have resulted in more hilar masses and endophytic tumours being offered NSS [1, 3].

Half of the overall NSS patients were hilar tumours in our series. Overall, most series have approximately 20–30% of hilar tumours [13, 14]. Our institute is a tertiary / quarternary referral centre with surgical robot. Patients with hilar tumours, who were offered radical nephrectomy in secondary care centres were either referred by their physicians or patients themselves presented for the option of NSS. This could be the reason for the higher proportion of hilar tumours in our series.

Though CECT is the radiological investigation of choice, with 3D reconstruction of vascular pattern [15]. MRI alone was used without contrast in one of our patients (Figs. 6, 7). With specific sequences, exact vascular anatomy could be delineated for successful vascular delineation. Good preoperative planning with imaging is necessary for intra sinus dissection and avoiding bleeding and positive margins [13].

Surgical technique for hilar tumours needS to be modified a little from the classical non-hilar partial nephrectomy [16]. After dissecting the vessels and looping them, intrasinus dissection is done to separate the tumour from

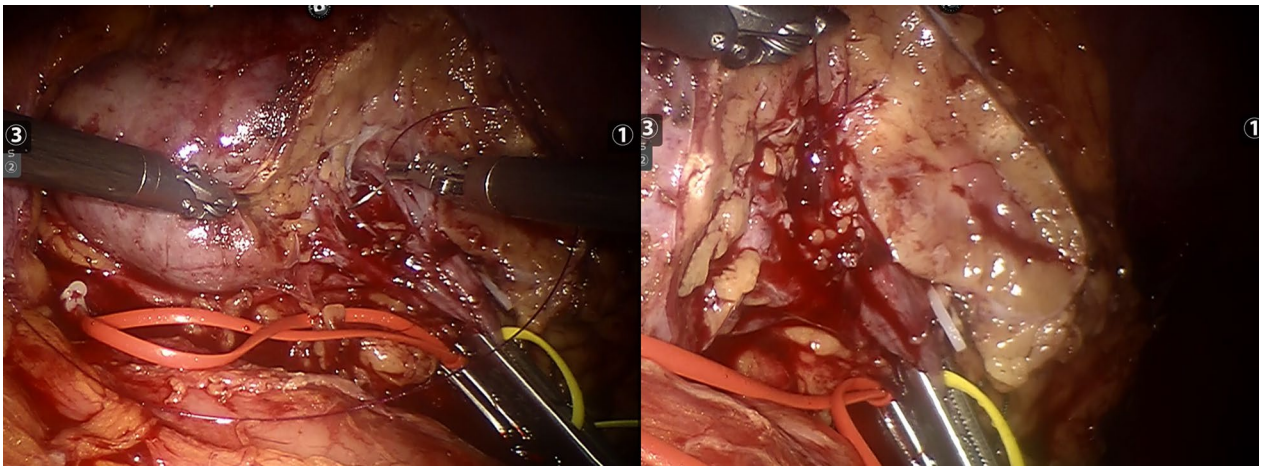

Fig. 3 Intraoperative photograph showing renal vein tributary tear managed with primary suturing

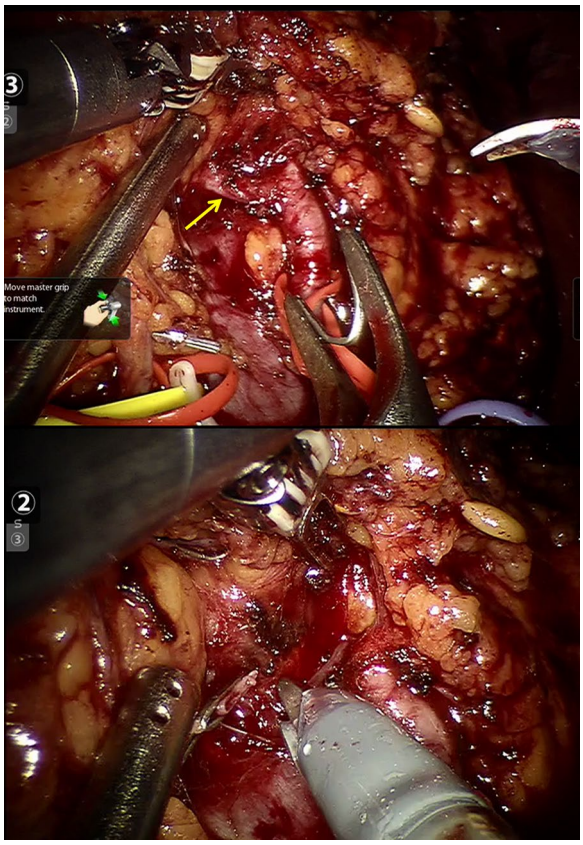

Fig. 4 Intraoperative photograph showing arterial branch supplying tumour (Yellow arrow) delineated by intra sinus dissection, clipped and divided

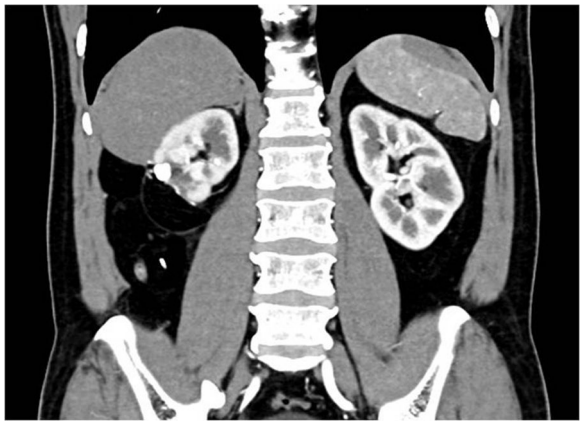

Fig. 5 CECT at 2 years follow-up showing normal remnant kidney perfusion and yellow arrow indicating previously embolised pseudoaneurysm

the vessel (Fig. 8). We could selectively clip the vessel supplying the tumour by intrasinus dissection, under clear vision, especially with the use of robot (Fig. 8). This helps to avoid sacrificing major branches and tributaries while dividing the tumour, which is usually associated with bleeding and poor vision if no clamps or isolated arterial clamps are used. One patient required reconstruction of renal vein tributaries in the tumour bed. Postoperatively, renal function was fairly preserved in the ipsilateral kidney on renogram.

The median WIT of 36 min, though higher than the recommended standard of less than 30 min, is acceptable for NSS [17]. The safe duration of warm ischaemia is debatable [18, 19]. There may be no specific reason for definite increase in hilar tumours, since the technique involves maximum mobilisation of tumour and intra sinus dissection before vessel clamping. We prefer isolated arterial clamping with venous 'perfusion' intact. Our sample size is small to have conclusive evidence, but we found no detrimental effects on Se. Creatinine and estimated glomerular filtration rate in the short duration follow-up. 10% decrease in renal function is expected in overall eGFR after partial nephrectomy [20]. Estimation of GFR by isotope renogram is ideal, but studies have found overall eGFR to correlate with the residual renal function [21].

Three patients developed complications. One patient required angioembolisation for pseudoaneurysm. Angioembolisation was done 'electively' without the patient having any symptoms like hematuria. Studies with elective CECT show an incidence of 20% for asymptomatic pseudoaneurysm following NSS [22]. Symptomatic pseudoaneurysm was found in 2% of patients [23]. The patient who developed urinoma, had double ureter and pelvis. The calyceal suture approximating both walls of one upper calyceal infundibulum was the cause of leak. This may not be attributable to the hilar nature of the tumour. Patient with T2a tumour developed urinoma and T1b grade 3 clear cell carcinoma patient needed angioembolisation. High grade and high stage tumours may be more prone to complications [24, 25].

One patient had 1 mm positive surgical margin. He had no recurrence at follow-up of 3 years. The management of patients with positive surgical margins is close monitoring. Though few studies suggest increased risk of recurrence, there is no role for radical nephrectomy. Higher stage and grade tumours were found to have positive margin, but the contribution of tumour behaviour as such, or the positive margin contributing to recurrence is debatable [26–28].

Infiltration of renal artery and vein is very rare. Though images indicate closely abutting tumour, definite planes are usually present and tumour could be dissected. But, the need for conversion to radical nephrectomy should be explained to all patients planned for NSS, especially in those with hilar tumours.

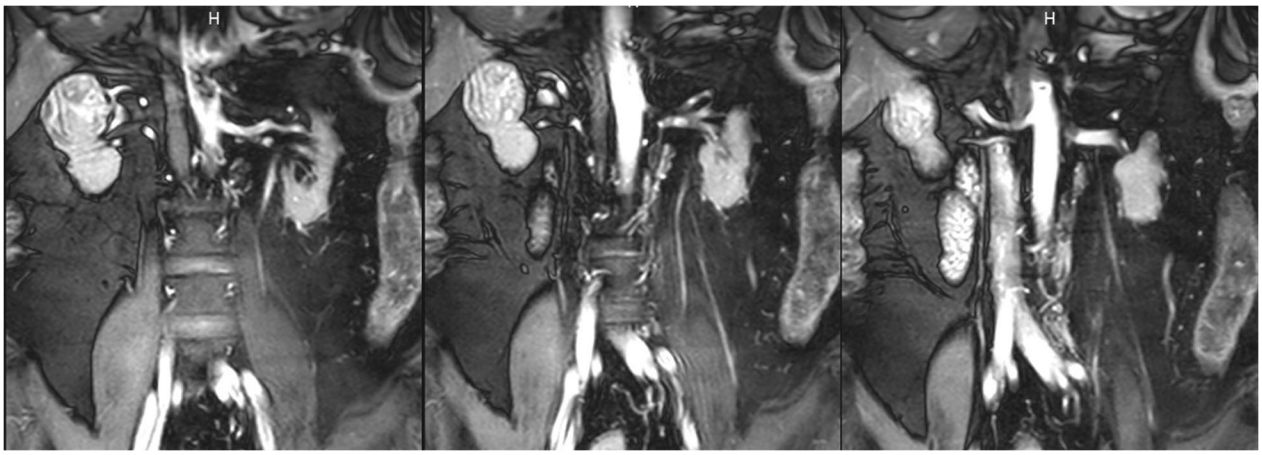

Fig. 6 MRI sagittal image showing tumour with renal vessel anatomy

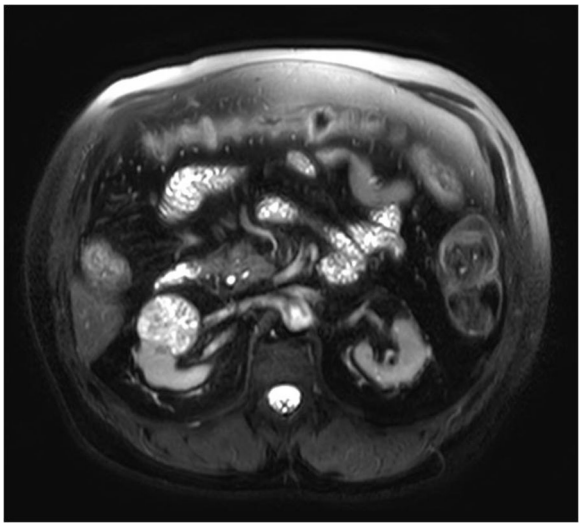

Fig. 7 MRI axial section showing tumour with renal vessels

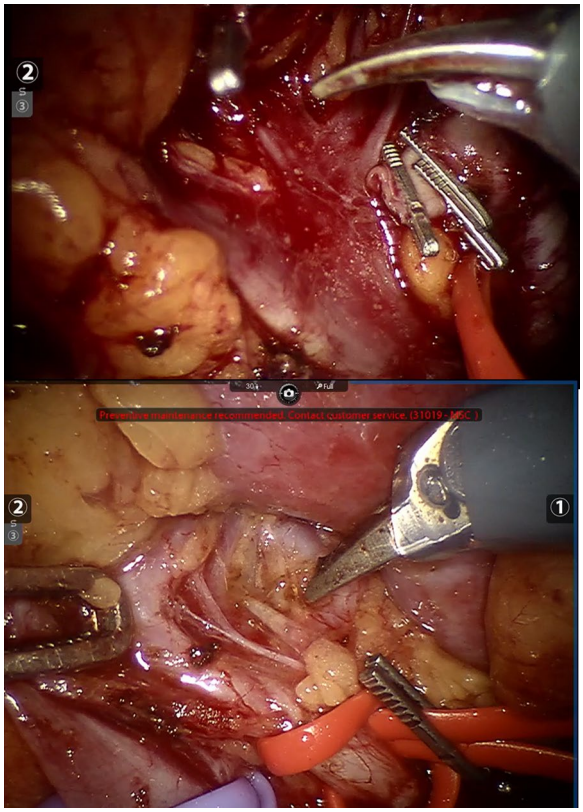

Fig. 8 Intrasinus dissection showing renal vein tributaries and renal arterial branches

The limitation of our study is the small sample size. We found it plausible to present with such small number, since we found almost half of our NSS patients had hilar tumours (Tumours close to or impinging on the vessels). The other limitation is the non inclusion of nephrometry score. We did not include it, since the scoring incorporates size and exophytic status which may confound the results of exclusive hilar tumours. The duration of follow-up is small to detect recurrence, but the patient with positive margin had two years follow-up with no recurrence. Isotope renogram would have been ideal to assess the effect of warm ischaemia of ipsilateral kidney.

5 Conclusion

Renal hilar tumours are not uncommon. They can be managed with nephron sparing surgery with acceptable complication rate and comparable prognosis. Robot-assisted intrasinus dissection is helpful in better preservation of renal parenchyma.

Abbreviations

NSS	Nephron saving surgery
CECT	Contrast-enhanced computed tomography
MRI	Magnetic resonance imaging
CKD	Chronic kidney disease
GFR	Glomerular filtration rate

Supplementary Information

The online version contains supplementary material available at https://doi.org/10.1186/s12301-024-00410-9.

Additional file 1: Fig. S1. First layer closure.

Additional file 2: Fig. S2. Second layer closure.

Additional file 3: Fig. S3. Third layer closure

Additional file 4. Masterchart.

Acknowledgements
None.

Author contributions
MA contributed in conception, design of the work, the acquisition, analysis, interpretation of data; drafted the work, preparation of manuscript and approved the submitted version; RC contributed in data interpretation and preparation of manuscript; DM contributed in data interpretation and preparation of manuscript; MA, RC, DM, all have read and approved the manuscript.

Funding
No funding utilised.

Availability of data and materials
Data and Material are available with the authors for clarification if required.

Declarations

Ethics approval and consent to participate
This study was approved by the ethics committee of KMCH Institute of Medical Sciences and Research.

Consent for publication
The patient provided consent for using his case details for publication.

Competing interests
No competing interests.

Received: 18 December 2023 Accepted: 4 January 2024
Published online: 22 January 2024

References

1. Campbell SC, Clark PE, Chang SS, Karam JA, Souter L, Uzzo RG (2021) Renal mass and localized renal cancer: evaluation, management, and follow-up: AUA guideline: part I. J Urol 206(2):199–208
2. Rogers CG, Metwalli A, Blatt AM, Bratslavsky G, Menon M, Linehan WM et al (2008) Robotic partial nephrectomy for renal hilar tumors: a multi-institutional analysis. J Urol 180(6):2353–2356
3. Abreu AL, Gill IS, Desai MM (2011) Zero- ischaemia robotic partial nephrectomy (RPN) for hilar tumours. BJU Int 108(6b):948–954
4. Dahlkamp L, Haeuser L, Winnekendonk G, von Bodman C, Frey UH, Epplen R et al (2019) Interdisciplinary comparison of PADUA and RENAL scoring systems for prediction of conversion to nephrectomy in patients with renal mass scheduled for nephron sparing surgery. J Urol 202(5):890–898
5. Correa AF, Yankey H, Li T, Joshi SS, Kutikov A, Chen DY et al (2019) Renal hilar lesions: biological implications for complex partial nephrectomy. Urology 1(123):174–180
6. Veccia A, Falagario U, Martini A, Marchioni M, Antonelli A, Simeone C et al (2021) Upstaging to pT3a in patients undergoing partial or radical nephrectomy for cT1 renal tumors: a systematic review and meta-analysis of outcomes and predictive factors. Eur Urol Focus 7(3):574–581
7. Chen L, Deng W, Luo Y, Liu W, Li Y, Liu X, Wang G, Fu B (2022) Comparison of robotassisted and laparoscopic partial nephrectomy for renal hilar tumors: results from a tertiary referral center. J Endourol 36(7):941–946
8. Murugesan A (2022) Robot-assisted ipsilateral partial nephrectomy with distal ureterectomy for synchronous renal and ureteric tumors-a case report. J Egypt Natl Cancer Inst 34(1):49
9. Capitanio U, Bensalah K, Bex A, Boorjian SA, Bray F, Coleman J et al (2019) Epidemiology of renal cell carcinoma. Eur Urol 75(1):74–84
10. Huang WC, Donin NM, Levey AS, Campbell SC (2020) Chronic kidney disease and kidney cancer surgery: new perspectives. J Urol 203(3):475–485
11. Lesage K, Joniau S, Fransis K, Van Poppel H (2007) Comparison between open partial and radical nephrectomy for renal tumours: perioperative outcome and health-related quality of life. Eur Urol 51(3):614–620
12. Clark PE, Schover LR, Uzzo RG, Hafez KS, Rybicki LA, Novick AC (2001) Quality of life and psychological adaptation after surgical treatment for localized renal cell carcinoma: impact of the amount of remaining renal tissue. Urology 57(2):252–256
13. Tyagi S, Sharma G, Bora GS, Mavuduru RS, Sharma AP, Devana SK, Gorsi U, Kakkar N, Singh SK (2021) Trifecta and pentafecta outcomes following robot-assisted partial nephrectomy for hilar versus nonhilar tumors: a propensity-matched analysis. Indian J Urol 37(4):318–324
14. Lattouf JB, Beri A, D'Ambros OF, Grüll M, Leeb K, Janetschek G (2008) Laparoscopic partial nephrectomy for hilar tumors: technique and results. Eur Urol 54(2):409–418
15. Tsili AC, Andriotis E, Gkeli MG, Krokidis M, Stasinopoulou M, Varkarakis IM et al (2021) The role of imaging in the management of renal masses. Eur J Radiol 1(141):109777
16. Gill IS, Colombo JR Jr, Frank I, Moinzadeh A, Kaouk J, Desai M (2005) Laparoscopic partial nephrectomy for hilar tumours. J Urol 174(3):850–853 (**discussion 853-4**)
17. Zhang Z, Zhao J, Velet L, Ercole CE, Remer EM, Mir CM et al (2016) Functional recovery from extended warm ischemia associated with partial nephrectomy. Urology 87:106–113
18. Abdel Raheem A, Alowidah I, Capitanio U, Montorsi F, Larcher A, Derweesh I et al (2022) Warm ischemia time length during on-clamp partial nephrectomy: does it really matter? Minerva Urol Nephrol 74(2):194–202
19. Deb AA, Agag A, Naushad N, Serag H (2022) Surgical and functional outcomes of artery only versus artery and vein clamping in patients undergoing partial nephrectomy: a systematic review and meta-analysis. Turk J Urol 48(3):180–195
20. Mir MC, Ercole C, Takagi T, Zhang Z, Velet L, Remer EM et al (2015) Decline in renal function after partial nephrectomy: etiology and prevention. J Urol 193(6):1889–1898
21. Kim CS, Bae EH, Ma SK, Kweon SS, Kim SW (2014) Impact of partial nephrectomy on kidney function in patients with renal cell carcinoma. BMC Nephrol 15(1):1–8
22. Yamashita S, Kawabata H, Deguchi R, Ueda Y, Higuchi M, Muraoka S et al (2021) Natural history of asymptomatic pseudoaneurysm soon after robot-assisted partial nephrectomy: single-center prospective study. Urology 148:145–150
23. Chavali JSS, Bertolo R, Kara O, Garisto J, Mouracade P, Nelson RJ et al (2019) Renal arterial pseudoaneurysm after partial nephrectomy: literature review and single-center analysis of predictive factors and renal functional outcomes. J Laparoendosc Adv Surg Tech A 29(1):45–50
24. Khene ZE, Mazouin C, Larcher A, Peyronnet B, Gasmi A, Roumiguié M et al (2022) Predicting complications after robotic partial nephrectomy: back to simplicity. Eur Urol Focus 8(3):777–783
25. Krane LS, Hemal AK (2013) Robotic and laparoscopic partial nephrectomy for T1b tumors. Curr Opin Urol 23(5):418–422
26. Antic T, Taxy JB (2015) Partial nephrectomy for renal tumors: lack of correlation between margin status and local recurrence. Am J Clin Pathol 143(5):645–651
27. Yossepowitch O, Thompson RH, Leibovich BC, Eggener SE, Pettus JA, Kwon ED et al (2008) Positive surgical margins at partial nephrectomy: predictors and oncological outcomes. J Urol 179(6):2158–2163

28. García-Perdomo HA, RibalCaparrós MJ, AlcarazAsensio A, Vilaseca Cabo A (2022) Effect of positive surgical margins in patients who undergo a partial nephrectomy regarding recurrence, overall survival, recurrence/progression-free survival, and metastasis free survival. A systematic review and meta-analysis. Clin Genitourin Cancer 20(5):459–472

Publisher's Note