

Case Report

Spermatic Cord Liposarcoma and Prostate Adenocarcinoma: a Synchronous Association

A. Adam¹, C. K. Adofo¹, K. K. Ijane¹, J. E. Dinkel², R. A. Feilat¹

¹Department of Urology, Kalafong Hospital, and ²Department of Anatomical Pathology, University of Pretoria, Tshwane, South Africa

ABSTRACT

Spermatic cord liposarcoma is rare, with fewer than a 100 reported cases in the world literature. We report on its presence in an elderly man who presented with a painless scrotal mass. The serum prostate specific antigen (PSA) level was also found to be elevated. Transrectal ultrasound biopsy of the prostate confirmed the presence of adenocarcinoma. This is the first report of prostatic adenocarcinoma in association with spermatic cord liposarcoma in the English literature. The treatment options for spermatic cord liposarcoma are discussed further.

Key Words: Spermatic cord, paratesticular liposarcoma, prostate adenocarcinoma, synchronous, scrotal mass

Corresponding Author: Dr. Ahmed Adam, PO Box 322, Lenasia, 1820, Johannesburg, Gauteng, South Africa, Email: aadam81@gmail.com

Article Info : Date received: 17/1/2010

Date accepted (after revision): 7/5/2010

INTRODUCTION

Paratesticular liposarcomas comprise only 0.056 percent of soft tissue sarcomas in general¹⁻². Fewer than a 100 cases of spermatic cord liposarcoma have been reported in the literature¹⁻³. We describe the first case of its synchronous presence along with adenocarcinoma of the prostate.

CASE REPORT

A 70-year-old retired gold miner presented with a painless scrotal swelling which began as a small left scrotal mass and gradually increased in size over a period of 5 years. The patient had no systemic or lower urinary tract symptoms or history of antecedent trauma.

On examination a firm, rubbery mass was palpated in the left inguinal region extending into the scrotum. A cough impulse could not be elicited and the inguinal lymph nodes were not palpable.

The scrotum was diffusely enlarged, with a large, non-tender, irreducible, mass. Digital rectal examination and urine dipstick analysis were normal.

The serum markers of testicular tumour were not elevated. The serum prostate specific antigen was elevated (22.9µg/l).

Scrotal ultrasonography revealed a large, solid, inhomogenous, poorly defined mass occupying the left hemiscrotum, not attached to the left testis.

Surgical exploration via a left, extended inguino-scrotal incision revealed a well-circumscribed mass in the inguinal canal extending into the scrotum (Figure 1). High ligation of the left spermatic cord with complete excision of the mass and ipsilateral testis was performed.

Pathology

Macroscopically, the specimen consisted of a well-circumscribed, encapsulated, soft tissue mass originating from the spermatic cord and measuring 16 x 13 x 12.5 cm (Figure 2). The testis and epididymis appeared normal (Figure 3).

Histological examination showed features consistent with a well-differentiated

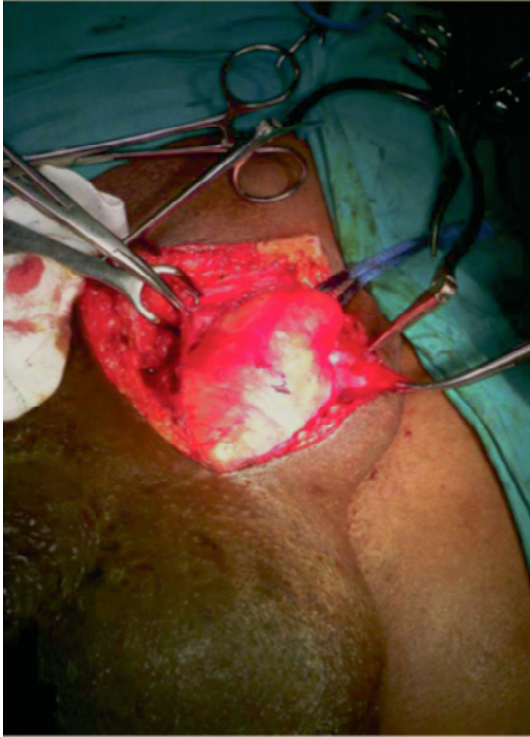

Fig. 1: Intra-operative photograph of the mass in the left inguinal canal.

liposarcoma, adipocytic type (Figure 4a). In occasional sections scattered large atypical hyperchromatic stromal cells, some of which were multinucleated, were seen (Figure 4b). No dedifferentiated component was identified. The testis showed focal, mild atrophy. The epididymis showed no significant abnormalities. The tumour resection margins were clear.

Transrectal ultrasound biopsy of the prostate revealed an adenocarcinoma (Gleason score 2+3).

Magnetic resonance imaging (MRI) of the region did not reveal any metastatic disease.

Despite adequate counseling, the patient refused further treatment.

DISCUSSION

In the paratesticular region, neoplastic disease may arise from the spermatic cord (commonest), epididymis, mesenchymal layers surrounding the testis or the true appendages¹.

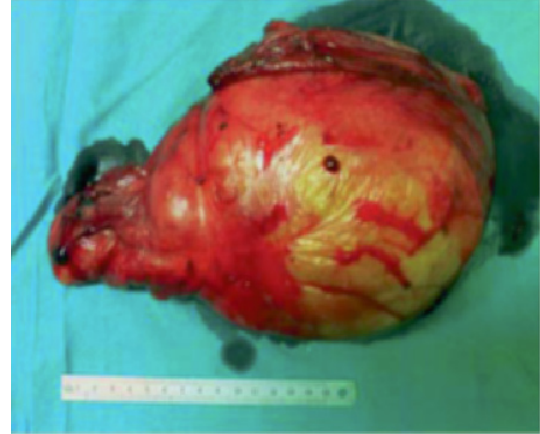

Fig. 2: Photograph of the paratesticular mass (weight 1,47 kg).

Since the first reported case of paratesticular liposarcoma (1952), its aetiology remains unknown^{1,3-4}.

These tumours occur most commonly between the ages of 54 and 88 years and show a right sided predominance^{1,3}.

They may spread via the local, haematogenous and lymphatic routes²⁻³.

The well-differentiated type carries a more favourable prognosis, with a 5-year survival of around 90 percent. This type has no potential to metastasize, unless it undergoes dedifferentiation^{2-3,5}.

The dedifferentiated liposarcomas carry a far worse prognosis, with a metastatic rate of up to 20% and tend to behave like the adult high grade pleomorphic sarcomas³.

Paratesticular liposarcoma commonly presents as a painless scrotal mass which gradually increases in size over months to years^{1,3}. It is often misdiagnosed as an inguinal hernia or hydrocele, since it may transilluminate¹⁻³.

Initial imaging should include inguino-scrotal ultrasonography^{2-3,6}. On account of its variable consistency, paratesticular liposarcoma is commonly misdiagnosed as a cystic or fatty lesion^{2-3,6}.

MRI and computed tomography (CT) are useful to assess the extent of local disease and metastases²⁻³.

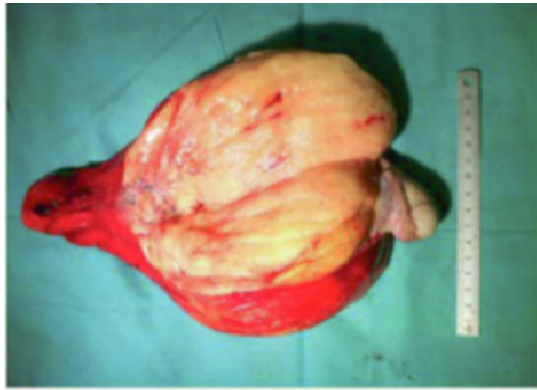

Fig. 3: Transected specimen showing a gelatinous surface, with the testis and epididymis separate from the mass.

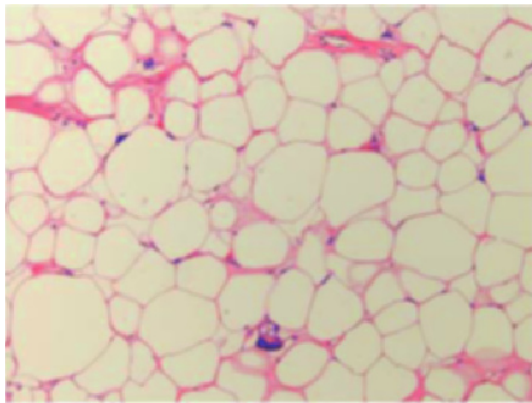


Fig. 4a: Histological section showing well-differentiated liposarcoma, (adipocytic type) with hyperchromatic stromal cells (H&E stain, 10X).

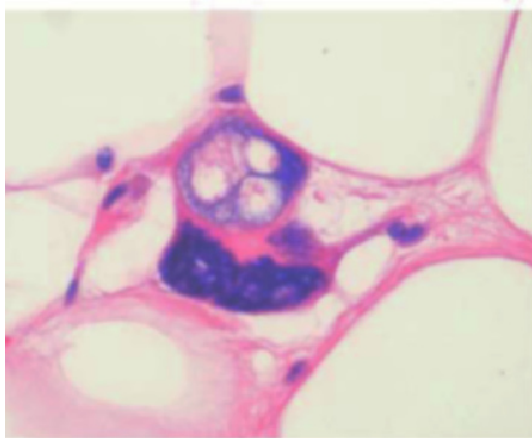


Fig. 4b: High magnification showing a large multi-nucleated atypical stromal cell (H&E stain, Zoom)

The recommended treatment of paratesticular sarcoma is radical orchidectomy with high spermatic cord ligation, since positive surgical margins are a predictor of early local recurrence^{1,7}.

Because it generally resembles a lipoma, both macro- and microscopically, and is mostly indolent, most authorities suggest that the type of tumor described here may be better designated as “atypical lipomatous tumor” except if it arises in the retroperitoneum, when it should be called “well-differentiated liposarcoma”⁸.

Since liposarcomas are the most radiosensitive of all sarcomas, radiation therapy alone has achieved remission in some cases^{1,3}.

The risk of recurrence of paratesticular liposarcoma post resection warrants long-term follow-up^{1-4,6}.

The incidence of multiple primary malignancies in an individual with cancer is estimated at four percent, with at least 14 percent of these cancers originating from the genitourinary system⁹.

A case of a spermatic cord liposarcoma has been described in a patient four years after radical retropubic prostatectomy for prostate cancer¹⁰. However, our case is the first report in the English literature of synchronous occurrence of these tumours.

With a common age group of presentation, synchronous association of these tumours could be merely co-incidental.

Acknowledgements

The authors are grateful to Prof. CDM Fletcher (Surgical Pathology, Harvard Medical School, Boston, Massachusetts, USA) for his assistance with the histological assessment and review.

We also wish to thank Dr. M. Louw (Anatomical Pathology, University of Pretoria) for the micro-photographs and Ms. M.Brassel (University of Pretoria, Library) for assistance with the literature search.

REFERENCES

1. Schwartz SL, Swierzewski SJ 3rd, Sondak VK, Grossman HB. Liposarcoma of the spermatic cord: Report of 6 cases and review of the literature. *J.Urol.* 1995; Jan;153(1):154-7.

2. Kalyvas KD, Kotakidou R, Trantos A, Yannakoyorgos K, Hatzichristou DG. Paratesticular well-differentiated, adipocytic type liposarcoma presenting as inguinal hernia. *Urol.Int.* 2004;72(3):264-8.
3. Sparks DA, Chase D, Farrell T, Abdul Ghani. Dedifferentiated paratesticular myxoid liposarcoma: A case report and review of literature. *Curr.Urol.* 2009;3(1):44-8.
4. Allaparthi S. Liposarcoma of the spermatic cord: A case report and review of the literature. *Internet J.Urol.* 2007;4(2).
5. Hassan JM, Quisling SV, Melvin WV, Sharp KW. Liposarcoma of the spermatic cord masquerading as an incarcerated inguinal hernia. *Am.Surg.* 2003; Feb;69(2):163-5.
6. Maximilian B, Joachim T, Sebastian M. Liposarcoma of the spermatic cord: Report of two cases and review of the literature. *Internet J.Urol.* 2005;3(1).
7. Rabbani F, Wright J, McLoughlin M. Sarcomas of the spermatic cord: Significance of wide local excision. *Can.J.Urol.* 1997;4(2):366-76.
8. Weiss SW, Goldblum JR. Enzinger and Weiss's *Soft Tissue Tumors*. 4th ed. St. Louis: Mosby; 2001: p 661-2.
9. Weingartner K, Melekos MD, Gerharz EW, Kohl U, Neumann K, Riedmiller H. Multiple (five) synchronous primary malignant neoplasms of dissimilar histogenesis including a malignant fibrous histiocytoma of the bladder. *Int.Urol.Nephrol.* 1995;27(2):157-66.
10. Yoshino T, Yoneda K, Shirane T. First report of liposarcoma of the spermatic cord after radical prostatectomy for prostate cancer. *Anticancer Res.* 2009;29(2):677-80.

Editorial Comment

The scientific content is OK and the histology pictures are representative of a well differentiated liposarcoma of the lipoma-like subtype.

This is a low grade malignancy of relatively mature adipocytes that exhibit focal atypia. It does not metastasize unless it “dedifferentiates”. Hence, careful sampling of the tumor to search for a dedifferentiated component is of utmost importance. Because, it generally looks like a lipoma, both grossly and microscopically, and because of its mostly indolent behavior, most authorities suggest that such a tumor is better designated “atypical lipomatous tumor” except if it arises in the retroperitoneum when it should be called “well differentiated liposarcoma”. I suggest that the authors should emphasize the above mentioned information in their discussion and clarify that they have sampled the tumor thoroughly to exclude the presence of dedifferentiated areas. Review of the following references is recommended in this context:

- Kempson RL, Fletcher CDM, Evans HL, Henrickson MR, Sibley RS. *Tumors of the Soft Tissues, Atlas of Tumor Pathology, AFIP Third Series, Fascicle 30*, 2001
- Fletcher CDM, Unni KK, Mertens F. *Pathology and Genetics of Tumours of Soft Tissue and Bone*, World Health Organization Classification of Tumours 2002
- Weiss SW, Goldblum JR. *Enzinger and Weiss's Soft Tissue Tumors*, 4th edition, 2001

Prof. Mohamed El-Shawarby

Professor of Pathology, Prof of Pathology, University of Dammam, Saudi Arabia

Authors' Reply

Indeed cases of atypical lipomatous tumours of the spermatic cord region have to be classified as well differentiated liposarcoma, adipocytic type. I can assure the editor that the mass was extensively sampled and no dedifferentiated component was identified.

Dr. Jurg E. Dinkel

Co-Author and Pathologist

The pathology report was reviewed by another expert in the field of histopathology prior to first submission, Prof. Fletcher (Harvard Medical School), who ironically happens to be an Author of the references that was recommended by your reviewer earlier. Thus, we have already mentioned him under the Acknowledgment section of our case report. We have also amended the pathology in the discussion section of the case report, as requested.

Dr. Ahmed Adam